

Microsurgical Varicocelectomy Treats Male Infertility


Improves Testosterone Levels As Well

New York (Nov 26, 2009)

Dr. Marc Goldstein

Microsurgical repair of varicoceles is known to improve semen quality and result in two to three times higher pregnancy rates compared to no treatment or other medical approaches for varicocele. (1) However, newer research shows that varicoceles are also associated with low testosterone levels and that microsurgical repair significantly increases serum testosterone levels in more than two-thirds of men. Thus, even men who are not concerned with fertility may benefit from this surgical treatment.

Varicoceles are found in approximately 15% of the general male population but in a higher percentage of infertile men who have never fathered a child (35%) or who once fathered a child but are now infertile (81%). (2,3)



How Do Varicoceles Cause Male Infertility?

The exact cause of infertility among men with varicocele is not clearly understood, however, researchers believe that varicoceles interfere with the countercurrent heat exchange mechanism in the testicles. "As the arteries to the testicles approach each testicle, they become very tightly wound like a radiator coil and are normally surrounded by a fine network of veins. This network helps exchange heat," explained Dr. Goldstein, Surgeon-in-Chief of Male Reproductive Medicine and Surgery and Director of the Center for Male Reproductive Medicine and Microsurgery at the New York-Presbyterian Hospital/Weill Cornell Medical Center. If the veins become enlarged because of higher pressure in the veins or poorly functioning valves, the heat exchange mechanism does not work properly causing elevated intratesticular temperature and impairing their ability to make sperm.

In addition to the effects on fertility, research by Dr. Goldstein and others has shown that the elevated intratesticular temperature caused by varicoceles can impair the testes' ability to make testosterone by negatively affecting testicular Leydig cell function. Thus, varicocele may put men at risk for the adverse effects of low testosterone level, such as low sex drive, erectile problems, decreased muscle strength, osteopenia/osteoporosis, and depression.

A Study That Supports This Theory

Dr. Goldstein and colleagues performed a retrospective chart review on 327 men ages 18-70 years who had undergone nyp.org/.../microsurgical-varicocelecto...

subinguinal microsurgical varicocelectomy for clinically palpable varicoceles. (4) These men had significantly lower serum testosterone levels compared with a control group of men with or without varicoceles who did not undergo the procedure (416 ± 164 ng/dL versus 469 ± 192 ng/dL, $P < 0.001$). This association was not altered by patient age. Compared with baseline, the patients' serum testosterone levels were significantly higher after microsurgical varicocelectomy (358 ± 126 ng/dL versus 454 ± 168 ng/dL, $P < 0.001$). In addition, 70% of men who underwent the procedure showed an increase in serum T levels post-operatively. The findings were presented at the 2007 annual meeting of the American Society for Reproductive Medicine and are expected to be published shortly.

What is a Microsurgical Varicocelectomy?

Dr. Goldstein uses the mini-incision, subinguinal microsurgical varicocelectomy with delivery of the testicle. The gubernacular veins and external spermatic perforators are also inspected and divided. Gubernacular veins in particular have been shown to cause of up to 10% of varicocele recurrences. The testicle is then returned to the scrotum and the spermatic cord is placed on a large Penrose drain. He then inspects the spermatic cord under a microscope and divides and ligates or clips all dilated internal spermatic veins. Postoperatively, venous return is via the deferential (vasal) veins, which drain into the internal pudendal veins and usually have competent valves. This approach allows the varicoceles to be removed while preserving the testicular artery, which is only 0.5-1.5-mm in diameter. The magnification also allows for identification and preservation of the lymphatics surrounding the testes, which reduces the risk of hydrocele. The procedure was pioneered by Dr. Goldstein (5) as well as Joel L. Marmar, MD, of Robert Wood Johnson Medical School, Camden, New Jersey.

Patients who respond best to varicocelectomy are those with large varicoceles in whom the veins can be felt and seen from the outside (ie, grade III varicoceles). Varicoceles first appear in adolescence and worsen slowly over time. Dr. Goldstein advocates repairing large varicoceles when they first appear in adolescents because "it is much easier to prevent future infertility than to treat it once the damage has already occurred." The sooner varicoceles are repaired the better the chance of halting future damage, he said.

NewYork-Presbyterian Hospital/Weill Cornell Medical Center, has the largest experience in the world in the use of microsurgical techniques for the treatment of male reproductive disorders, including varicocelectomy and vasectomy reversals, Dr. Goldstein said. "Very few major IVF [in vitro fertilization] centers have a reproductive urologist on staff. If a man has any sperm at all, they bypass the male altogether and start IVF. Here, physicians from the male and female reproductive divisions work together as a team to provide optimal care for the couple rather than just treating one partner separately." In at least half of these couples, the man could be treated and the couple could achieve a pregnancy without IVF, notes Dr. Goldstein. "We can use simpler, more economical treatments that are easier for women like IUI (intrauterine insemination) or a natural conceived pregnancy." In addition, for men who have zero sperm count, varicocelectomy can allow for enough sperm to be produced in their semen to allow for IVF or, if they remain at zero sperm count, can improve sperm production enough inside the testicle that it can be extracted with an operating microscope (microdissection testicular sperm extraction) for use in IVF/Intracytoplasmic sperm injection.

Faculty Contributing to this Article:

Marc Goldstein, MD is Surgeon-in-Chief of Male Reproductive Medicine and Surgery, Executive Director of the Men's Service Center of the Cornell Institute for Reproductive Medicine, and Director of the Center for Male Reproductive Medicine and Microsurgery at the NewYork-Presbyterian Hospital/Weill Cornell Medical Center. He is also the Matthew P. Hardy Distinguished Professor of Reproductive Medicine and a Professor of Urology at Weill Cornell Medical College. Additionally, he is a Senior Scientist with the Population Council's Center for Biomedical Research, located on the campus nyp.org/.../microsurgical-varicocelecto...

References:

1. Marmar JL, Agarwal A, Prabakaran S, et al. Reassessing the value of varicocelectomy as a treatment for male subfertility with a new meta-analysis. *Fertil Steril.* 2007;88(3):639-648.
2. Thomas AM and Fariss BL. The prevalence of varicoceles in a group of healthy young men. *Mil Med.* 1979;144:181-182.
3. Gorelick JI and Goldstein M. Loss of fertility in men with varicocele. *Fertil Steril.* 1993;59: 613-616.
4. Tanrikut C, Choi JM, Rosoff JS, Nelson CJ, Mulhall JP, Goldstein M. Improvement in serum testosterone levels after varicocelectomy. *Fert Stert.* 2008;88(suppl):S386.
5. Goldstein M, Gilbert BR, Dicker AP, Dwosh J, Gnecco C. Microsurgical inguinal varicocelectomy with delivery of the testis: An artery and lymphatic sparing technique. *J. Urol.* 1992;148:1808-1811.

© New York-Presbyterian Hospital

Columbia University College of Physicians & Surgeons Weill Medical College of Cornell University

available at www.sciencedirect.com
journal homepage: www.europeanurology.com



European Association of Urology



Andrology

Does Varicocele Repair Improve Male Infertility? An Evidence-Based Perspective From a Randomized, Controlled Trial

Taha A. Abdel-Meguid^{a,b,*}, Ahmad Al-Sayyad^a, Abdulmalik Tayib^a, Hasan M. Farsi^a

^a Department of Urology, King Abdulaziz University Medical City, Jeddah, Saudi Arabia

^b Department of Urology, El-Minia University, El-Minia, Egypt

Article info

Article history:

Accepted December 10, 2010

Published online ahead of
print on December 21, 2010

Keywords:

Evidence-based infertility
Male infertility
Pregnancy
Subfertile men
Varicocele
Varicocelectomy
Varicocele repair

Abstract

Background: Randomized controlled trials (RCTs) addressing varicocele treatment are scarce and have conflicting outcomes.

Objective: To determine whether varicocele treatment is superior or inferior to no treatment in male infertility from an evidence-based perspective.

Design, setting, and participants: A prospective, nonmasked, parallel-group RCT with a one-to-one concealed-to-random allocation was conducted at the authors' institution from February 2006 to October 2009. Married men 20–39 yr of age who had experience infertility ≥ 1 yr, had palpable varicoceles, and with at least one impaired semen parameter (sperm concentration < 20 million/ml, progressive motility $< 50\%$, or normal morphology $< 30\%$) were eligible. Exclusions included subclinical or recurrent varicoceles, normal semen parameters, and azoospermia. Sample size analysis suggested 68 participants per arm.

Intervention: Participants were randomly allocated to observation (the control arm [CA]) or subinguinal microsurgical varicocelectomy (the treatment arm [TA]). Semen analyses were obtained at baseline (three analyses) and at follow-up months 3, 6, 9, and 12. The mean of each sperm parameter at baseline and follow-ups was determined.

Measurements: We measured the spontaneous pregnancy rate (the primary outcome), changes from baseline in mean semen parameters, and the occurrence of adverse events (AE—the secondary outcomes) during 12-mo follow-up; $p < 0.05$ was considered significant.

Results and limitations: Analysis included 145 participants (CA: $n = 72$; TA: $n = 73$), with a mean age plus or minus standard deviation of 29.3 ± 5.7 in the CA and 28.4 ± 5.7 in the TA ($p = 0.34$). Baseline characteristics in both arms were comparable. Spontaneous pregnancy was achieved in 13.9% (CA) versus 32.9% (TA), with an odds ratio (OR) of 3.04 (95% confidence interval [CI], 1.33–6.95) and a number needed to treat (NNT) of 5.27 patients (95% CI, 1.55–8.99). In CA within-arm analysis, none of semen parameters revealed significant changes from baseline (sperm concentration [$p = 0.18$], progressive motility [$p = 0.29$], and normal morphology [$p = 0.05$]). Conversely, in TA within-arm analysis, the mean of all semen parameters improved significantly in follow-up versus baseline ($p < 0.0001$). In between-arm analysis, all semen parameters improved significantly in the TA versus CA ($p < 0.0001$). No AEs were reported.

Conclusions: Our RCT provided level 1b evidence of the superiority of varicocelectomy over observation in infertile men with palpable varicoceles and impaired semen quality, with increased odds of spontaneous pregnancy and improvements in semen characteristics within 1-yr of follow-up.

© 2010 European Association of Urology. Published by Elsevier B.V. All rights reserved.

* Corresponding author. Department of Urology, King Abdulaziz University Hospital, PO Box 80215, Jeddah, 21589, Saudi Arabia. Tel. +966501304345; Fax: +96626408440.
E-mail address: tahaaboalmagd@yahoo.com (T.A. Abdel-Meguid).

1. Introduction

Infertility affects 10–15% of couples endeavoring to conceive, with male infertility contributing to nearly 50% of cases [1]. Varicoceles are the most prevalent abnormal physical finding in male infertility, with a prevalence of 19–41% of men with primary infertility and 45–81% of men with secondary infertility [1,2].

Although varicocele repair procedures have been extensively practiced over several decades in the domain of male infertility, the fundamental question regarding their beneficial effect on male fertility remains unresolved. Numerous conflicting individual reports and systematic reviews on outcomes of varicocele treatment have been published in the literature, with many studies claiming improvements in pregnancy rates and semen characteristics [2–10] and other reports denying any benefit [11–16]. Despite randomized controlled trials (RCTs) being considered the gold standard and most powerful tool in contemporary clinical research [17], a number of systematic reviews concluded that properly conducted RCTs addressing varicocele treatment are quite scarce and have contradictory outcomes [2–4,11,12]. In addition, RCTs can yield biased results if they lack methodologic rigor [17]. In the era of evidence-based medicine (EBM), it seems inappropriate to either widely practice or reject varicocele treatment based solely on outcomes of inadequately designed studies or conflicting expert opinions.

The current study undertook to determine the superiority or inferiority of varicocele treatment versus no treatment in infertile men with palpable varicoceles and impaired semen quality by addressing the effects on pregnancy rates and semen characteristics in a prospective, randomized, controlled, parallel fashion, providing level 1b evidence in this regard.

2. Materials and methods

2.1. Setting

The study was conducted at the authors' institution between February 2006 and October 2009. The study received ethical committee approval, and informed consent was obtained from each participant prior to enrollment.

2.2. Study design

The study was designed in a prospective, one-to-one concealed-to-randomization, controlled, parallel-group, nonblinded, open-label fashion.

2.3. Outcome measures

The primary outcome measure was determining spontaneous pregnancy rate during a 12-mo period after receiving the allocated intervention. Secondary outcomes were changes from the mean baseline of each semen parameter (sperm concentration, motility, normal morphology) and the occurrence of adverse events (AEs) during the designated 12-mo period.

2.4. Sample size

To estimate the sample size prior to commencing the study, an effect size of 21.5% improvement in pregnancy rate within 1 yr following varicocele repair was postulated. The effect size was based on previous studies [5,6,14,16] that had similar inclusion–exclusion criteria but diverse pregnancy outcomes concluding superiority [5,6] versus nonsuperiority of varicocele treatment [14,16]. The mean pregnancy rate in these studies was 38.5% in treated patients versus 17.05% in nontreated patients. To accomplish a statistical power of 80% and by setting the alpha level at 5%, a sample size of 68 patients per arm was essential in double-sided testing. We determined a sample size of 75 patients per arm, allowing up to seven patients to drop out.

2.5. Inclusion criteria

Married, overall healthy men 20–39 yr of age who had had infertility for >1 yr of unprotected intercourse, clinically palpable unilateral or bilateral varicoceles (grades 1–3), and impaired semen quality (at least one of the following semen characteristics: sperm concentration <20 million/ml, progressively motile sperm <50%, or morphologically normal sperm <30%) were considered eligible for the study.

2.6. Exclusion criteria

Patients with unilateral or bilateral subclinical or recurrent varicoceles, normal semen parameters, azoospermia, an abnormal hormonal profile, additional causes of infertility, significant medical diseases, smoking, occupational heat exposure, female partner ≥ 35 yr of age, associated female factor infertility, or unstable marriage were deemed ineligible. Patients who refused randomization were excluded from study entry. Patients who explicitly elected or rejected surgery or initially elected to have an observation period before considering surgery afterwards were excluded as well to avoid undermining the randomization process.

2.7. Baseline period

Palpable varicoceles on physical examination were further documented by scrotal ultrasound. All patients underwent three-semen analyses within a 3-mo baseline period, with as constant a number of days of sexual abstinence (3–5 d) as possible. Patients were instructed to avoid using any medications that might affect their semen quality or fertility potential throughout the baseline and study periods.

2.8. Randomization and allocation to intervention

Eligible patients were offered the option of receiving immediate varicolectomy or observation for 1 yr with subsequent reevaluation of the management plan and possible delayed varicolectomy. Eligible patients who declared willingness to equally accept either option on a random basis were enrolled as participants and were allocated at a balanced one-to-one ratio to either immediate varicolectomy (the treatment arm [TA]) or observation (the control arm [CA]). A simple random allocation sequence was computer generated and concealed by an independent research assistant. Randomization–allocation concealment to both investigators and participants was ascertained by using sequentially numbered opaque envelopes containing the assigned intervention. However, neither the participants nor the investigators were blinded to the intervention after allocation.

2.9. Interventions

TA patients underwent subinguinal microsurgical varicolectomy with arterial and lymphatic sparing [7] within a maximum of 4 wk following

the last baseline semen analysis. CA patients were allocated to observation only.

2.10. Follow-up

Participants were followed for 12 mo after the day of surgery (TA) or the day of the last baseline semen analysis (CA). Any pregnancy that might occur during the study period was documented. Repeated semen analyses were obtained at follow-up months 3, 6, 9, and 12. All participants were assessed for adverse effects (AEs) throughout study period, while TA patients were evaluated at the 6-mo follow-up, with physical examination and scrotal ultrasound to assess varicocele recurrence, hydrocele formation, and testicular size.

2.11. Statistical analysis

Unpaired Student *t* test for between-arm analysis, paired student *t* test for within-arm analysis, and Fisher exact tests for dichotomous variables were performed using SPSS v.16.0 software (SPSS, Chicago, IL, USA). A two-tailed *p* value <0.05 was considered statistically significant. The mean plus or minus standard deviation (SD) of each semen parameter was calculated for the three-semen analyses conducted

during the baseline period, then for the 12-mo follow-up semen analyses. The number needed to treat (NNT; reciprocal of absolute risk difference) was calculated for the dichotomous outcome of spontaneous pregnancy, representing the number of patients to be treated to achieve an extra pregnancy. The confidence interval (CI) around the NNT was calculated using the Schulzer method.

3. Results

Initially, 150 participants were randomly and equally allocated to either the TA or CA. Two participants in the TA and three participants in the CA were excluded from analysis, leaving the final number analyzed at 145 participants. The Consolidated Standards of Reporting Trials chart (Fig. 1) demonstrates the flow of participants through the trial. The mean age plus or minus SD was 29.3 ± 5.7 yr of age in the CA and 28.4 ± 5.7 yr of age in the TA, with an insignificant difference ($p = 0.34$). Baseline demographic, clinical, and semen characteristics of the analyzed patients in both arms were comparable with insignificant differences (Tables 1 and 2).

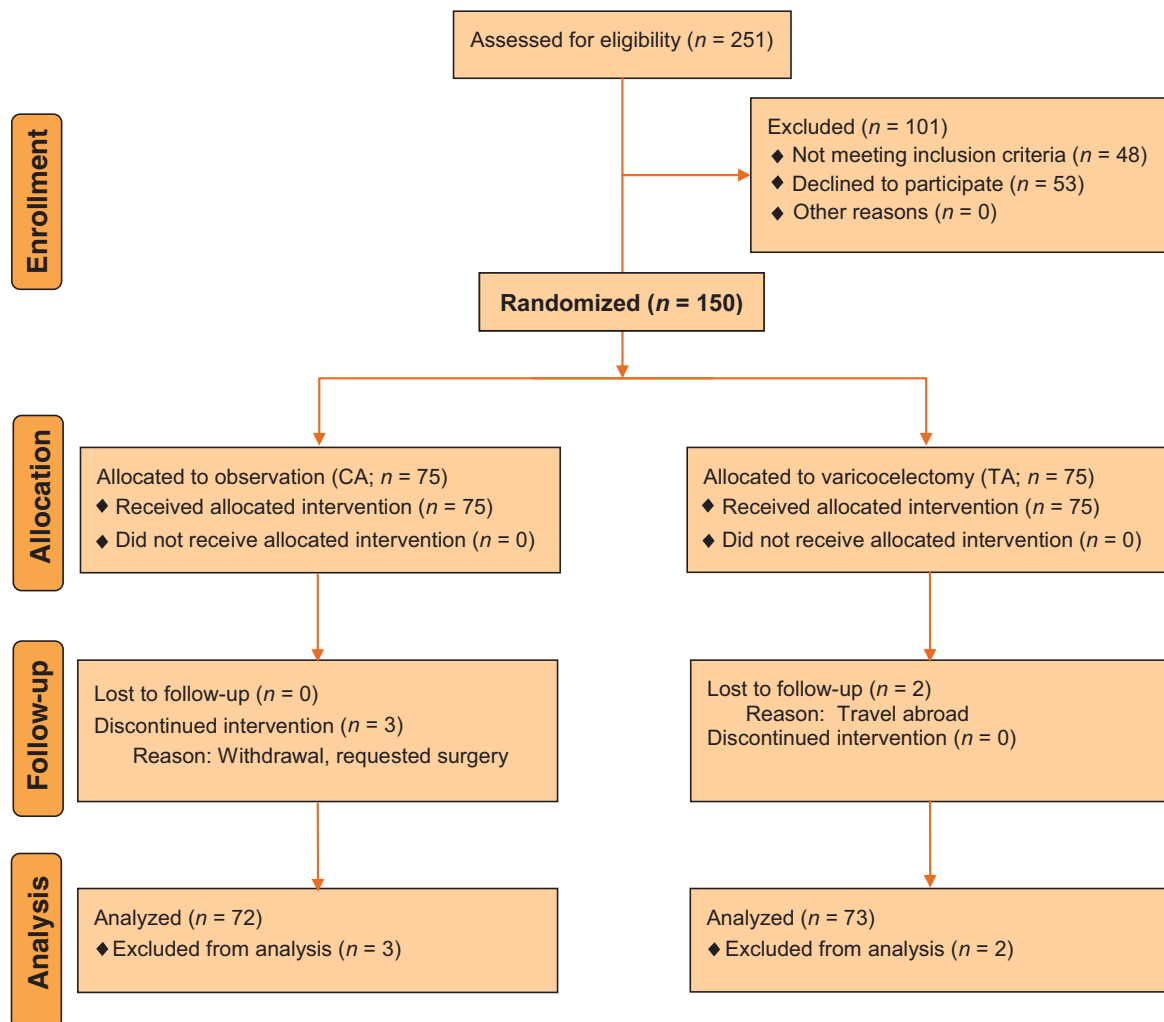


Fig. 1 – Consolidated Standards of Reporting Trials flow chart for the trial.
CA = control arm; TA = treatment arm.

Table 1 – Baseline characteristics of the treatment and control arms

Parameter	CA (n = 72)	TA (n = 73)	p value
Age of participants, yr	29.3 ± 5.7	28.4 ± 5.7	0.34
Age of wife, yr	25.8 ± 4.3	25.3 ± 4.1	0.47
Duration of infertility, mo	17.8 ± 4.9	18.5 ± 5.1	0.40
Infertility, no. (%)			
Primary	38/72 (52.8)	40/73 (54.8)	>0.99
Secondary	34/72 (47.2)	33/73 (45.2)	>0.99
Varicocele, side, no. (%)			
Unilateral, left	53/72 (73.6)	53/73 (72.6)	>0.99
Unilateral, right	0/72 (0)	0/73 (0)	>0.99
Bilateral	19/72 (26.4)	20/73 (27.4)	>0.99
Total sides	91	93	-
Varicoceles (n = 93) grade, no. (%)			
Grade 1	36/91 (39.6)	38/93 (40.9)	>0.99
Grade 2	30/91 (33)	28/93 (30.1)	>0.99
Grade 3	25/91 (27.5)	27/93 (29)	>0.99

CA = control arm; TA = treatment arm.

Spontaneous pregnancy was achieved in 13.9% of the CA compared to 32.9% of the TA, with an odds ratio (OR) of 3.04 (95% CI, 1.33–6.95) and an NNT of 5.27 patients (Table 3). The mean age of wives who achieved pregnancy was 26.1 ± 4.4 yr of age in the CA versus 27.2 ± 4.6 yr of age in the TA—an insignificant difference (p = 0.52; 95% CI, –2.37 to 4.59).

Semen parameter changes are shown in Table 2. In CA within-arm analysis, none of the semen parameters revealed significant changes from baseline, with p = 0.18 for sperm concentration, p = 0.29 for progressive motility, and p = 0.05 for normal morphology. Conversely, in TA within-arm analysis, the mean of all semen parameters improved significantly during follow-up versus baseline (p < 0.0001). In between-arm analysis, all semen parameters improved significantly in the TA versus the CA (p < 0.0001). No AEs were reported in either the TA or CA, and none of the TA patients demonstrated evident recurrent varicocele, hydrocele formation, or changed testicular size during follow-up.

4. Discussion

In the realm of EBM, although RCTs are considered the gold standard and best tool in evaluating health care interventions, providing level 1 evidence [17], only a few clinical situations can be managed in a real EBM setting in urology [18]. Few RCTs addressing the effect of varicocele repair on pregnancy outcome and semen characteristics have been published in the literature, with most of them subject to major criticism [2–4]. Ficarra et al, in their systematic review of available RCTs addressing the treatment of varicoceles for male infertility, reported that some RCTs included men with subclinical varicoceles or normal semen parameters, while others had poor methodologic quality, poor recruitment, significant drop-outs after randomization, or inadequate statistical power [4]. They concluded that the current literature does not provide enough data to draw any favorable or adverse conclusions, and data from

Table 2 – Changes in semen parameters in both arms

Semen parameter	Within-arm analysis* CA (n = 72)		Within-arm analysis* TA (n = 73)		Between-arm analysis**	
	Mean ± SD (range)	p	Mean ± SD (range)	p	p	D (95% CI)
Sperm concentration, million/ml	17.5 ± 6 (9.1–27.2)	–	18.1 ± 5.8 (8.5–34.8)	–	0.5	0.66 (–1.3 to 2.6)
	17.2 ± 6.4 (8.5–28.4)	0.18	32.2 ± 10.6 (13.3–46.6)	<0.0001	<0.0001	15 (12.1–17.9)
Motility, %	26.1 ± 11.9 (16–57)	–	25.3 ± 12.8 (15–55)	–	0.7	–0.8 (–4.9 to 3.3)
	25.8 ± 12.5 (15–55)	0.29	41.0 ± 10 (25–60)	<0.0001	<0.0001	15.2 (11.5–18.9)
Normal morphology, %	30.9 ± 4.2 (26–42)	–	31.2 ± 4.1 (27–40)	–	0.62	0.34 (–1.0 to 1.7)
	31.1 ± 4.2 (26–40)	0.05	39.1 ± 4.5 (33–49)	<0.0001	<0.0001	8.03 (6.6–9.5)

CA = control arm; TA = treatment arm; SD = standard deviation; D = mean difference; CI = confidence interval.
* Paired t test.
** Unpaired t test.

Table 3 – Pregnancy rates in both arms

	Within-arm analysis		<i>p</i>	Between-arm analysis		
	CA (<i>n</i> = 10 of 72)	TA (<i>n</i> = 24 of 73)		D	OR	NNT
Pregnancy, % (95% CI)	13.9 (7–24)	32.9 (22–45)	0.01	19 ± 0.8 (5.19–32.78)	3.04 (1.33–6.95)	5.27 (1.55–8.99)
Age of pregnant wives, yr ± SD (95% CI)	26.1 ± 4.4	27.2 ± 4.6	0.52	1.11 (–2.37 to 4.59)	–	–

CA = control arm; TA = treatment arm; D = mean difference; CI = confidence interval; OR = odds ratio; NNT = number needed to treat.

ongoing studies should provide more information on this topic [4].

In the current study, concealed randomization–allocation at a one-to-one balanced ratio was implemented to eliminate selection bias. Stringent inclusion–exclusion criteria were adopted in an attempt to ensure better homogeneity and comparability of baseline characteristics in the trial arms, to reduce the risk of imbalance resulting from confounding factors, and consequently to better identify and quantify the effect size of intervention. Similarly, to eliminate age as a confounder and obviate the controversies regarding fertility potential and outcomes of varicocelectomy in younger or older age groups [19–22], we limited our study to couples with males between 20 and 39 yr of age and females younger than 35 yr of age. Likewise, patients with subclinical or recurrent varicoceles, normal semen parameters, or azoospermia were considered ineligible. We did not include patients who requested specific management—whether observation or varicocelectomy—to avoid undermining the randomization process. In addition, sample size analysis was performed prior to recruiting patients to ensure adequacy of the study's statistical power. Establishing the traditionally accepted 80% statistical power with 5% alpha level conferred reliability to our significantly positive findings. To further support the reliability of our findings, although a study with lesser power (from a statistical viewpoint) may allow a small positive effect size to be overlooked, a less powered study would advocate treatment if significant effects were observed [16].

Because pregnancy is the ultimate goal for infertility patients, we adopted spontaneous pregnancy rate as the primary outcome measure, while changes in semen parameters were used as a secondary outcome. Investigations using semen parameter changes as the primary outcome measures for the efficacy of varicocele treatments provide only indirect evidence, given that pregnancy is the only outcome parameter at venture [2–4]. Besides, semen parameters demonstrate extensive intra- and interindividual variability and overlapping between fertile and infertile men [23,24]. In our study, with a comparable mean age among females capable of conceiving in both arms, spontaneous pregnancy was documented in 13.9% of the CA versus 32.9% of the TA, a difference that is statistically significant ($p = 0.01$) and favoring repair of varicoceles. Patients in the TA have an appealingly higher OR of 3.04 (95% CI, 1.33–6.95) for achieving spontaneous pregnancy compared to the CA. The magnitude of effect and clinical importance of varicocelectomy is further conveyed by the NNT of 5.27 patients (95% CI, 1.55–8.99), meaning that we

need to treat 5.27 patients to achieve an extra spontaneous pregnancy within 1 yr after varicocelectomy. Our pregnancy outcomes are consistent with previous studies, supporting the beneficial effects of varicocele repair on the fertility status of males with palpable varicoceles and impaired semen quality [3,4].

In two independent meta-analyses reviewing RCTs, Ficarra et al. [4] reported a pregnancy rate of 36.4% and 20%, while Marmar et al. [3] reported 33% and 15.5% pregnancy rates in patients who underwent varicocele treatment compared to no treatment, respectively. Contrary to our findings, Nieschlag et al, in an RCT comparing varicocele treatment to counseling, found pregnancy rates not significantly different in both groups (29% vs 25%, respectively) at the end of the 12-mo study period, suggesting that counseling is as effective as treatment in achieving pregnancy [14]. Although that study was methodologically sound, it has a high dropout rate of 38.4%, jeopardizing its findings. Similarly, Evers and Collins systematic reviews [11,12] found no difference in the odds of pregnancy in varicocele-treated patients compared with no treatment, suggesting no benefit for varicocele treatment. However, in their meta-analyses, they included patients with subclinical varicoceles or normal semen characteristics. In addition, the lack of difference may be the result of not reporting pregnancy as a main outcome variable. Including large studies reporting only limited pregnancy data may give these studies more weight and would cause the overall conclusion to be weighted toward no effect [3].

Despite extensive variations in sperm characteristics, several studies linked better pregnancy outcomes to better semen parameters [2]. The chances of pregnancy in a Danish report increased with increasing sperm density up to 40 millions/ml [25]. Similarly, normal sperm motility [26] and sperm morphology [27] were identified as powerful discriminators differentiating between fertile and infertile men. In a meta-analysis to determine the efficacy of varicocelectomy in improving semen parameters in infertile men with palpable varicoceles and abnormal semen analysis, all semen parameters improved significantly following varicocelectomy [2]. In our study, superior improvements of semen characteristics in the TA versus the CA were evident. In within-arm analysis, all semen parameters improved significantly in the TA (<0.0001), while none of these parameters showed significant change in the CA. In addition, in between-arm analysis, semen characteristic changes in the TA were significantly different (<0.0001) from the CA, favoring treatment.

Our findings endorse the belief that varicocelectomy is an effective treatment for improving semen parameters in infertile men with clinically palpable varicoceles [2]. Besides the evident superiority of varicocele repair in our study, none of the patients in either arm encountered any AE, further supporting the previously reported safety of subinguinal and microsurgical procedures with arterial and lymphatic sparing [7–9,28].

For practical reasons, this study was conducted as open label without masking to either participants or investigators, with the inherent bias of unmasking [17]. However, assessing objective rather than subjective outcomes in our study might reduce such bias.

5. Conclusions

Our study provided an evidence-based endorsement (level 1b evidence) of the superiority of varicocele repair over observation in infertile men with palpable varicoceles and impaired semen quality. The study exhibited the beneficial effect of varicocelectomy on the odds of spontaneous pregnancy and improvements in semen characteristics within 1 yr.

Author contributions: Taha A. Abdel-Meguid had full access to all the data in the study and takes responsibility for the integrity of the data and the accuracy of the data analysis.

Study concept and design: Abdel-Meguid.

Acquisition of data: Abdel-Meguid, Al-sayyad, Tayib, Farsi.

Analysis and interpretation of data: Abdel-Meguid.

Drafting of the manuscript: Abdel-Meguid.

Critical revision of the manuscript for important intellectual content: Abdel-Meguid, Al-sayyad, Tayib, Farsi.

Statistical analysis: Abdel-Meguid.

Obtaining funding: None.

Administrative, technical, or material support: Abdel-Meguid.

Supervision: Abdel-Meguid, Al-sayyad, Tayib, Farsi.

Other (specify): None.

Financial disclosures: I certify that all conflicts of interest, including specific financial interests and relationships and affiliations relevant to the subject matter or materials discussed in the manuscript (eg, employment/affiliation, grants or funding, consultancies, honoraria, stock ownership or options, expert testimony, royalties, or patents filed, received, or pending), are the following: None.

Funding/Support and role of the sponsor: None.

Acknowledgment statement: The authors acknowledge Professor Dr. Hisham A. Mosli, Professor of Urology, King Abdulaziz University Medical City, Jeddah, Saudi Arabia, for providing thorough and thoughtful revision and criticism for the study and Dr. Mohamad Hani Abd-Alwahhab, senior registrar of urology, for assisting in data collection.

References

- [1] Cocuzza M, Cocuzza MA, Bragais FMP, Agarwal A. The role of varicocele repair in the new era of assisted reproductive technology. *Clinics* 2008;63:395–404.
- [2] Agarwal A, Deepinder F, Cocuzza M, et al. Efficacy of varicocelectomy in improving semen parameters: new meta-analytical approach. *Urology* 2007;70:532–8.
- [3] Marmar JL, Agarwal A, Prabakaran S, et al. Reassessing the value of varicocelectomy as a treatment for male subfertility with a new meta-analysis. *Fertil Steril* 2007;88:639–46.
- [4] Ficarra V, Cerruto MA, Liguori G, et al. Treatment of varicocele in subfertile men: the Cochrane review – a contrary opinion. *Eur Urol* 2006;49:258–63.
- [5] Madgar I, Weissenberg R, Lunenfeld B, Karasik A, Goldwasser B. Controlled trial of high spermatic vein ligation for varicocele in infertile men. *Fertil Steril* 1995;63:120–4.
- [6] Hargreave TB. Varicocele: overview and commentary on the results of the World Health Organisation varicocele trial. In: Waites GMH, Frick J, Baker GWH, editors. *Current Advances in Andrology, Proceedings of the VIth International Congress of Andrology*; Salzburg, Austria. May 25–29, 1997; Bologna, Italy: Monduzzi Editore; 1997. p. 31–44.
- [7] Marmar JL, Kim Y. Subinguinal microsurgical varicocelectomy: a technical critique and statistical analysis of semen and pregnancy data. *J Urol* 1994;152:1127–32.
- [8] Goldstein M, Gilbert BR, Dicker AP, Dwosh J, Gnecco C. Microsurgical inguinal varicocelectomy with delivery of the testis: an artery and lymphatic sparing technique. *J Urol* 1992;148:1808–11.
- [9] Cayan S, Kadioglu TC, Tefekli A, Kadioglu A, Tellaloglu S. Comparison of results and complications of high ligation surgery and microsurgical high inguinal varicocelectomy in the treatment of varicocele. *Urology* 2000;55:750–4.
- [10] Sayfan J, Soffer Y, Orda R. Varicocele treatment: prospective randomized trial of 3 methods. *J Urol* 1992;148:1447–9.
- [11] Evers JL, Collins JA. Surgery or embolisation for varicocele in subfertile men. *Cochrane Database Syst Rev* 2004; CD000479.
- [12] Evers JLH, Collins JA. Assessment of efficacy of varicocele repair for male subfertility: a systematic review. *Lancet* 2003;361:1849–52.
- [13] Kamischke A, Nieschlag E. Varicocele treatment in the light of evidence based andrology. *Hum Reprod Update* 2001;7:65–9.
- [14] Nieschlag E, Hertle L, Fishedick A, Abshagen K, Behre HM. Update on treatment of varicocele: counselling as effective as occlusion of the vena spermatica. *Hum Reprod* 1998;13:2147–50.
- [15] Nilsson S, Edvinsson A, Nilsson B. Improvement of semen and pregnancy rate after ligation and division of the internal spermatic vein: fact or fiction? *Br J Urol* 1979;51:591–6.
- [16] Krause W, Muller HH, Schafer H, Weidner W. Does treatment of varicocele improve male fertility? Results of the “Deutsche Varikozelenstudie,” a multicentre study of 14 collaborating centres. *Andrologia* 2002;34:164–71.
- [17] Schulz KF, Altman DG, Moher D, the CONSORT Group. CONSORT 2010 statement: updated guidelines for reporting parallel group randomised trials. *BMJ* 2010;340:c332.
- [18] Novara G, Ficarra V, Artibani W. Evidence-based medicine: the supporting pillar of trial registration. *Eur Urol* 2009;56:956–8.
- [19] Kidd SA, Eskenazi B, Wyrobek AJ. Effects of male age on semen quality and fertility: a review of the literature. *Fertil Steril* 2001;75:237–48.
- [20] De La Rochebrochard E, Thonneau P. Paternal age ≥ 40 years: an important risk factor for infertility. *Am J Obstet Gynecol* 2003;189: 901–5.
- [21] Zini A, Boman J, Jarvi K, Baazeem A. Varicocelectomy for infertile couples with advanced paternal age. *Urology* 2008;72:109–13.
- [22] Robinson SP, Hampton LJ, Koo HP. Treatment strategy for the adolescent varicocele. *Urol Clin North Am* 2010;37:269–78.
- [23] Tielemans E, Heederik D, Burdorf A, Loomis D, Habbema DF. Intraindividual variability and redundancy of semen parameters. *Epidemiol* 1997;8:99–103.
- [24] Auger J, Eustache F, Ducot B, et al. Intra- and inter-individual variability in human sperm concentration, motility and vitality assessment during a workshop involving ten laboratories. *Hum Reprod* 2000;15:2360–8.

- [25] Bonde JP, Ernst E, Jensen TK, et al. Relation between semen quality and fertility: a population-based study of 430 first-pregnancy planners. *Lancet* 1998;352:1172–7.
- [26] Nallella KP, Sharma RK, Aziz N, et al. Significance of sperm characteristics in the evaluation of male infertility. *Fertil Steril* 2006;85:629–34.
- [27] Guzick DS, Overstreet JW, Factor-Litvak P, et al. Sperm morphology, motility, and concentration in fertile and infertile men. *N Engl J Med* 2001;345:1388–93.
- [28] Hirsch IH, Abdel-Meguid TA, Gomella LG. Postsurgical outcomes assessment following varicocele ligation: laparoscopic versus subinguinal approach. *Urology* 1998;51:810–5.

Reassessing the value of varicocelectomy as a treatment for male subfertility with a new meta-analysis

Joel L. Marmor, M.D.,^a Ashok Agarwal, Ph.D.,^b Sushil Prabakaran, M.D.,^b Rishi Agarwal,^b Robert A. Short, Ph.D.,^c Susan Benoff, Ph.D.,^d and Anthony J. Thomas, Jr., M.D.^b

^a Division of Urology, Robert Wood Johnson Medical School at Camden, Camden, New Jersey; ^b Reproductive Research Center, Glickman Urological Institute and Department of Obstetrics-Gynecology, Cleveland Clinic, Cleveland, Ohio; ^c Health Research and Education Center, Washington State University, Spokane, Washington; and ^d North Shore-LIJ Research Institute, Manhasset, New York

Objective: To determine the efficacy of varicocelectomy as a treatment for male factor infertility by improving the chance of spontaneous pregnancy.

Design: Meta-analysis.

Setting: Cleveland Clinic's Glickman Urological Institute.

Patient(s): Infertile men with abnormal results on semen analyses and a palpable varicocele.

Intervention(s): Surgical varicocelectomy.

Main Outcome Measure(s): Spontaneous pregnancy outcome.

Result(s): The odds of spontaneous pregnancy after surgical varicocelectomy, compared with no or medical treatment for palpable varicocele, were 2.87 (95% confidence interval [CI], 1.33–6.20) with use of a random-effects model or 2.63 (95% CI, 1.60–4.33) with use of a fixed-effects model. The number needed to treat was 5.7 (95% CI, 4.4–9.5).

Conclusion(s): Surgical varicocelectomy in infertile men with palpable lesions and at least one abnormal semen parameter improves the odds of spontaneous pregnancy in their female partners. Five studies were included (two randomized, three observational). All were scored for bias. Our study suggests that varicocelectomy in selected patients does indeed have beneficial effects on fertility status. (Fertil Steril® 2007;88:639–48. ©2007 by American Society for Reproductive Medicine.)

Key Words: Varicocelectomy, pregnancy, meta-analysis, random effect

Is a varicocelectomy an effective treatment for male factor subfertility? It is a seemingly simple question that has been the focus of intense debate for nearly 50 years. Many studies report improvement after surgery (1–9), but other studies show no benefit (10–17). Clearly, there are conflicting opinions whether a varicocelectomy improves fertility.

These differences of opinion are most obvious in the clinical guidelines for male factor infertility that have been published by various professional groups. For example, the

Best Policies Practice Groups of both the American Urological Association and the American Society for Reproductive Medicine (18, 19) have stated jointly that correction of varicoceles is indicated for infertile men with palpable lesions and one or more abnormal semen parameters. However, they specifically noted that treatment of the varicocele is not indicated in patients with normal results of semen analyses or subclinical, nonpalpable varicoceles. In contrast, the National Collaborating Centre for Women's and Children's Health, 2005 (11) stated, "Men should not be offered surgery for varicoceles as a form of fertility treatment because it does not improve pregnancy rates." The European Urological Association Guidelines on Male Infertility simply concluded that treatment of varicoceles to achieve pregnancies remains controversial (20). Thus, the fundamental question remains whether the existing literature on varicoceles is reliable enough to resolve these differences of opinion and serves as the basis of a new meta-analysis.

Although randomized controlled trials remain the "gold standard" or level I evidence, the current group of randomized

Received January 11, 2006; revised December 1, 2006; accepted December 5, 2006.

Supported by funds from the Reproductive Research Center and the Glickman Urological Institute, Cleveland Clinic, and by grant number ES10496 to S. B. from the National Institute of Environmental Health Sciences, National Institutes of Health, Bethesda, Maryland.

Reprint requests: Ashok Agarwal, Ph.D., Professor, Lerner College of Medicine, Case Western Reserve University, and Director, Reproductive Research Center, Glickman Urological Institute and Department of Obstetrics-Gynecology, Cleveland Clinic, 9500 Euclid Ave., Desk A19.1, Cleveland, OH 44195 (FAX: 216-445-6049; E-mail: agarwaa@ccf.org).

controlled trials on the subject of varicocelectomy and pregnancy outcome has been criticized for several reasons. The critics state that some randomized controlled trials included men with subclinical varicoceles or normal semen analyses and others had significant dropouts after randomization (11, 21–23). A recent critique concluded that analysis of the randomized controlled trial data in the current literature does not allow us to draw any favorable or adverse conclusions to the treatment of varicoceles in infertile couples (24).

Despite these criticisms, our group still believed that it might be possible to develop a new and reliable meta-analysis from the existing literature; however, such a meta-analysis would require several considerations that were fundamentally different. First, we would select only articles that included infertile men with palpable varicoceles who had at least one low semen parameter on three samples. Second, we would limit this study only to surgical repairs because there has been a difference of opinion regarding the outcomes with surgery compared with embolization (25, 26). Third, we would include only articles that reported data on the relationship of “surgical” varicocelectomies and “spontaneous or natural” pregnancy rates.

Furthermore, we would blind the articles for the reviewers and score them with our new scoring system to evaluate four types of study bias. Still further we would follow the lead of some investigators who have suggested that it is reasonable to include level II evidence from observational or case-controlled studies in a meta-analysis so long as the observational studies have considered carefully the potential for bias (21, 27). In various clinical situations, the existing evidence from randomized controlled trials addressing the effectiveness of specific interventions may be quite limited; therefore, it may not be inappropriate for systematic reviews to include carefully considered nonrandomized studies to provide a detailed picture of our current knowledge and limitations (28). Therefore, in the present meta-analysis on surgical varicocelectomy and spontaneous pregnancy, we intended to include both randomized controlled trials and observational studies (Fig. 1).

MATERIALS AND METHODS

Types of Patients

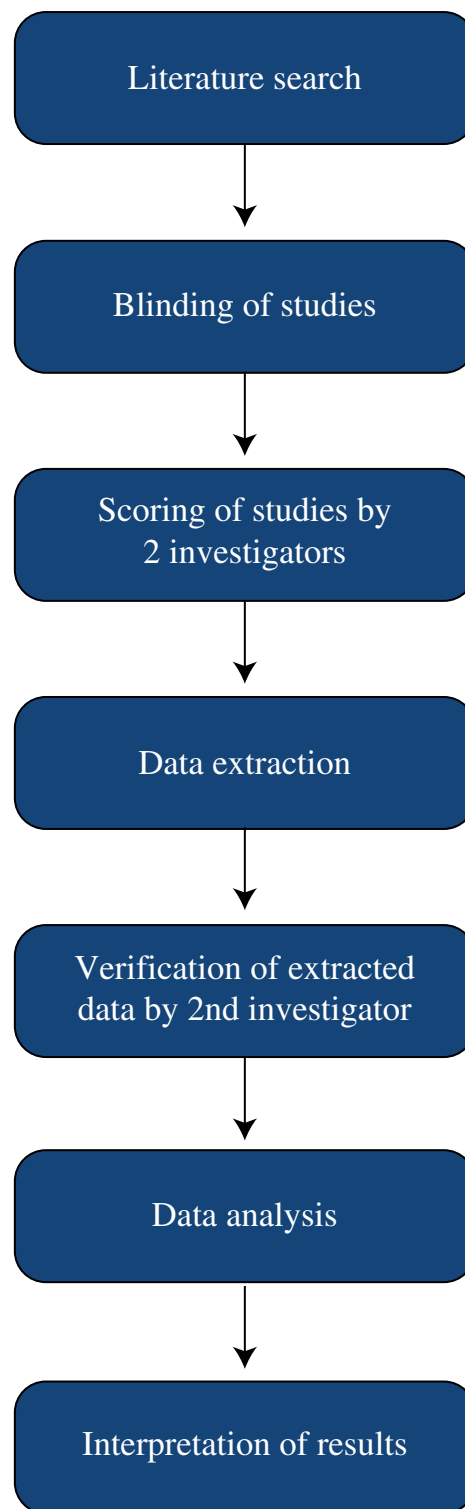
Studies of infertile men with a diagnosis of unilateral or bilateral palpable varicoceles and at least one abnormal semen parameter were included. Control groups were composed of infertile men with varicoceles who declined to undergo surgical repair and who were randomly assigned either to no treatment or to medical treatment.

Types of Intervention

Surgical varicocelectomy (high ligation, inguinal, or microsurgery) was reviewed.

FIGURE 1

Flow diagram on selection of studies for the meta-analysis.



Marmar. Varicocelectomy—a new meta-analysis. *Fertil Steril* 2007.

Types of Outcome Measure

The outcome measure was the effect of surgical varicocelectomy on natural or spontaneous pregnancy outcome during follow-up of up to 24 months.

Search Strategy for Identification of Studies

Studies were identified by performing an extensive search with BIOSIS, EMBASE, and Medline (from 1985 to present) with the help of a professional librarian, as well as by hand-searching review articles and cross-references. The overall strategy for study identification and data extraction is outlined in Figure 2. The following key words were used to search the databases: varicocelectomy, microsurgery, high ligation, infertility, semen parameters, and pregnancy rate or outcome. No exclusions were made on the basis of

language. Articles were evaluated for relevance by examining titles and abstracts. Studies were excluded if there were patients with subclinical varicoceles only or subclinical varicoceles combined with clinical varicocele and if the effect of treatment was examined only in an adolescent population.

Evaluation of Relevant Studies by Blinding and Scoring of Studies

All articles and reviewers were blinded during the evaluation period. The methods, results, tables, and figures from each study were extracted, and each article was assigned an identification number by an individual other than the two scorers. Actual quantitative or qualitative report of results was blacked out in each article to enable unbiased scoring of study quality. Data points or graphs were blacked out of figures, whereas axes and captions were still included for evaluation. Summary statistics, *P* values, or descriptions were blacked out of tables and texts, whereas labels such as comparison groups and parameters measured were left viewable. Two evaluators blinded to the concluding results, authors, journal, and year of the articles evaluated each study on its methodologic merits.

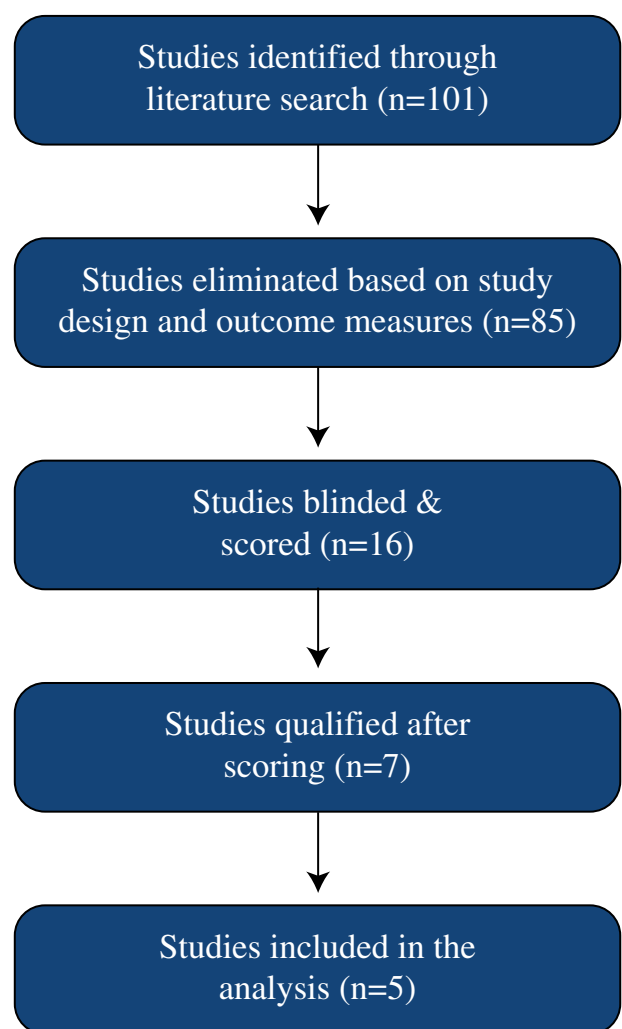
Articles with both preoperative and postoperative repeated measures of semen parameters were evaluated for methodologic quality by our initial scoring system (Appendix). The questions and scores were developed to evaluate four categories of bias: selection or follow-up bias, confounding bias, information or detection bias, and other sources of bias such as misclassification. Each study was scored by using the same set of questions for each type of bias (29, 30). Specific answers for different questions were given more weight than others as evidenced in the point system used to total the scores for each category of bias.

A higher score indicated that the study met most of the criteria required to avoid introducing bias in the study. If the point total for more than one category of bias was below an acceptable range, the study automatically was excluded from the final analysis. If the points for only one category totaled below the acceptable range, the study was reexamined to determine whether, indeed, the overall study was likely to be biased and, if not, whether it could be included in the meta-analysis.

The point ranges for exclusion or inclusion were determined by the epidemiologic importance of each study, its scientific quality, and the possibility of the article reaching a biased conclusion. For example, in the case of selection or follow-up biases, if a large proportion of subjects were lost to follow-up, then it becomes difficult to determine whether those who selectively dropped out may have been the ones with least improvement or whether the losses were simply too few in numbers to have biased the results. Thus, to deal with this potential quandary, a positive answer (no loss to follow-up over 10%) was given 2 points and a negative answer (loss to follow-up in more than 10% of participants) was given 1 point (Appendix). The same rationale was

FIGURE 2

Flow diagram on selection of studies evaluating the effect of varicocelectomy on the pregnancy outcome.



Marmar. Varicocelectomy—a new meta-analysis. *Fertil Steril* 2007.

carried out for all other sources of bias: confounding bias, information or detection biases, and other sources of bias such as misclassification. If information for a particular question was not stated, the study was given only 1 point for that question. Furthermore, the category of confounding was designed to include studies that made a comparison between the same subjects but not over more than a 2-year period. If the follow-up time was more than 2 years after the surgery, or with no follow-up within this time period, or if the study did not account for time-varying confounders, then it was likely that the study would be excluded.

This method of scoring studies was used rather than a simple checklist because the latter may produce bias (29). As an alternative, our scoring plan was intended to identify and quantify potential sources of bias. Two reviewers scored each study independently, and the final decision on whether a study was to be included was determined by discussion between the two reviewers.

Data Extraction

Data were extracted by one of the authors on a preformatted data extraction sheet. Population information (i.e., primary versus secondary infertility) and study characteristics such as the specific intervention (high ligation, microsurgery, and laparoscopy) were listed. These data were available for subsequent subgroup analyses.

The data were then entered in the RevMan software (version 4.2.8) developed by the Cochrane Collaborative for the purpose of meta-analysis (<http://www.cochrane.org>).

Effect of Varicocelectomy on Pregnancy Outcome

To examine the effect of varicocelectomy on “spontaneous or natural” pregnancy, we studied cohorts within a 2-year follow-up after varicocelectomy was performed in one male cohort and no, delayed, or medical treatment in the other cohort. Studies were excluded if they had men with subclinical varicoceles. Also, patients who had undergone assisted reproductive techniques (ART) such as IVF or IUI were not included in the analysis. Studies that used embolization or sclerosis techniques for varicocele corrections were excluded. Pregnancy data were recorded for the 24-month interval after surgery, and the overall odds were calculated by random-effects and fixed-effects models. The number needed to treat was calculated and evaluated by 95% confidence intervals (CI) (31). The number needed to treat was recalculated after removal of the most favorable study (1). All data were verified by a second investigator.

RESULTS

Of the 101 articles retrieved from the search containing pregnancy data, further elimination because of the study designs and relevance of outcomes measured was conducted, yielding 16 studies to be blinded. These 16 studies were then scored and assessed for quality. Two of these studies (15, 32) were excluded because they had both patients with surgical ligation and patients who had sclerosis or radiologic emboli-

zation. Patients whose partners achieved pregnancy with ART (IVF and/or IUI) were excluded from our analysis, but one of the included studies followed patients for spontaneous pregnancy after ART (4). The remainder of these studies were excluded on the basis of their scores for bias (Appendix). Therefore, our meta-analysis was limited to five surgical studies that included data on spontaneous pregnancy rates.

The mean age of the male cohorts was 31.2 years (range 20–46 years). Laterality was reported in four of the five studies. Left varicoceles were noted in 67.4% to 81.5% of the patients, bilateral varicoceles in 14.0% to 30.4%, and right varicoceles in 2.1% to 5.5%. The varicoceles were all palpable, but the specific sizes were recorded in only two of the five studies. Grade III (large) varicoceles were recorded in 9.5% and 34.3% of the patients, grade II (moderate) in 54.4% and 21.8%, and grade I (small) in 36.2% and 43.7%. The controls in four of the studies had no treatment, whereas in one study the controls used clomiphene citrate (Clomid).

The odds of spontaneous pregnancy after varicocelectomy compared with no or medical treatment for clinical varicocele were 2.87 (95% CI, 1.33–6.20, $P=.007$) with use of the inverse variance random-effects model (Table 1). A fixed-effects model also yielded a significant odds ratio of 2.63 (95% CI, 1.60–4.33], $P=.00001$). Results of the test for the presence of heterogeneity between study measures was not significant ($P=.17$).

Pregnancy outcome was also evaluated on the basis of the number needed to treat. Within the five studies there were 396 patients who underwent operation and who had 131 pregnancies (33.0%) versus 174 controls with 27 pregnancies (15.5%). The number needed to treat was 5.7 (95% CI, 4.1–9.5). When the data were recalculated after removal of the figures from the most favorable study (1), the number needed to treat was 6.6 (95% CI, 4.4–13.3), which represents comparable results following surgery.

DISCUSSION

A group of 20 scientists from nine countries, known as the Potsdam Consultation, convened to develop guidelines for the conduct and interpretation of meta-analyses. They added to the experience of earlier investigators and defined a meta-analysis as a systematic review that uses statistical methods to combine and summarize the results of several studies (29), and they listed 13 specific methodologic principles for the performance of these studies. In a separate study, Thacker et al. noted the benefits of a meta-analysis and stated that “decisions about clinical practice should be based on the combined weight of the evidence from available reports” (33). However, they warned that there are systematic rules for conducting a meta-analysis that include an explicit description of methodology so that results can be interpreted in light of any biases or limitations.

In the present meta-analysis, we examined the effect of surgical varicocelectomy on spontaneous pregnancy

TABLE 1

Confidence intervals and odds ratio for pregnancy after varicocelectomy among men with palpable lesions and at least one abnormal semen parameter.

Study	Varicocelectomy n/N	Control n/N	OR (random) 95% CI	OR (random) 95% CI
Grasso et al 2000	1 / 34	2 / 34		0.48 [0.04, 5.61]
Madgar et al 1995	16 / 25	2 / 20		13.50 [2.55, 71.40]
Marmar et al 1994	66 / 186	3 / 19		2.93 [0.82, 10.44]
Okuyama et al 1988	43 / 141	15 / 83		1.99 [1.02, 3.86]
Onozawa et al 2002	6 / 10	5 / 18		3.90 [0.76, 19.95]
Total (95% CI)	396	174		2.87 [1.33, 6.20]
Total events: 131 (Varicocelectomy), 27 (Control)				
Test for heterogeneity: $\text{Chi}^2 = 8.47$, $\text{df} = 4$ ($P = 0.17$), $r = 38.1\%$				
Test for overall effect $Z = 2.68$ ($P < 0.00001$)				

Note: OR = odds ratio; n = number of couples achieving pregnancy with male partners diagnosed with clinical varicoceles; N = total number of cases.

Marmar. Varicocelectomy—a new meta-analysis. Fertil Steril 2007.

outcome. We developed a different methodology than in previous meta-analyses: we adhered to the principles of the Potsdam guidelines, we “blinded” the reviewers during the evaluation process, and we developed a scoring system to quantify bias that was used to evaluate the literature on infertile men who had “surgical” correction of varicoceles. With this approach, the data from our meta-analysis led us to conclude that a surgical varicocelectomy improved the spontaneous pregnancy rates for infertile men with low semen parameters and palpable varicoceles. However, we believe that a critical discussion of our methods is necessary to understand the process.

A primary cause of bias in a meta-analysis can come from the reviewers. It is feasible that a reviewer may be influenced by the knowledge of institutions, investigators, and the concluding results associated with other aspects of the study (34). This has been termed inclusion bias (35). The mechanisms for inclusion bias have been reported (36), but they may be minimized by “blinding” the examiners and the documents during the evaluation process. Historically, the majority of meta-analyses have not been blinded. However, in the present meta-analysis we chose to make the effort and take particular precautions to proceed with blinded evaluations. In addition, we used other strategies to evaluate bias.

To evaluate the literature for bias, we developed a scoring system rather than a checklist (29). It is possible that a well-designed study with a traditionally acceptable checklist for inclusion (statement of randomization procedure, stated assessment of confounding, etc.) still may be biased because of unequal weighting. Some items on the checklist may value individual studies inappropriately over the others. Our scor-

ing plan was intended to adjust for this type of bias. In some instances, specialty groups have developed and used standardized protocols for scoring literature in their fields (37, 38). In the absence of standard methods in the present field, we developed our own scoring system to evaluate several types of bias. Although the scoring system was not validated statistically, during several meetings before the initiation of this meta-analysis we discussed and adopted a set of specific questions and point scores to limit quantitatively against potential bias in the literature under consideration. The new system was applied to the blinded manuscripts to determine their inclusion into the meta-analysis. Two reviewers scored each study, independently, and the final decision on inclusion or exclusion was determined during a discussion between the two reviewers. This approach has been considered and accepted in other fields for the development of other meta-analyses (38, 39).

Some investigators have been critical of the fact that most varicocele studies have been uncontrolled and not randomized controlled trials. In an attempt to address these matters, two recent meta-analyses have been published on varicoceles (10, 12) with only level I evidence from a group of randomized controlled trials. Essentially, these two meta-analyses included the same group of randomized controlled trials, and both reviews came to the conclusion that varicocele repairs do not improve subfertility. However, these meta-analyses, themselves, have been the subject of several critiques that have cited methodologic flaws that may have biased the results. Specifically, the National Collaborating Centre for Women’s and Children’s Health, 2005 report (11) was critical for several reasons: these meta-analyses

had clinical heterogeneity in the subjects selected, and there were differences in the mean age of the male partners, differences in the duration of infertility, and high dropout rates after randomization. In another critique, Templeton (22) commented that Evers and Collins (12) elected to exclude a large, hitherto-unpublished World Health Organization (WHO) study that appeared in abstract form. These WHO data suggested that varicocelectomy appeared to improve pregnancy, and, according to Templeton, “exclusion of the multi-centre data is important and could have made a difference” (22), which raises concerns for publication bias. In still other critiques, some investigators pointed out that four of the eight randomized controlled trials included in these meta-analyses had men with subclinical varicoceles, and two had men with normal semen parameters (23). For example, Ficarra et al. (24) reevaluated data from a prior meta-analysis (12) by removing studies that included men with subclinical varicoceles and normal semen parameters. When they recalculated the data for the “as-treated” groups, the pregnancy rates were 36.4% for the surgically treated group and 20% for controls ($P=0.009$). Therefore, these past meta-analyses have not resolved the issues surrounding varicocelectomy and subfertility. Nevertheless, our group believed that it was still possible to develop a new and more inclusive meta-analysis from the existing literature that may lead to valid conclusions.

In the present meta-analysis, we included both randomized controlled trials and observational studies. Although this approach may be controversial to some, we believe that it is sound for the current subject matter primarily because of the lack of reliable randomized controlled trial data. Several studies suggest that randomized controlled trials provide the highest level of evidence for causation, but they are known to be costly and difficult to complete, particularly without experiencing a significant number of dropouts after randomization (21, 27, 28). Furthermore, in some instances, the ethics of the randomized controlled trials may be viewed as borderline because the randomization and informed consent may not reach international standards, and in most cases they are done without peer review (40). Still further, some randomized controlled trials may be particularly unfair to infertile couples who are offered no treatment in one arm of the trial, when alternative treatment is available such as IVF (22). In these instances, treatment delays may expose these couples to the negative influence of advancing age on pregnancy outcome.

Because of these realities, we chose to include observational studies in addition to randomized controlled trials in the present meta-analysis. The Potsdam Consultation noted that observational studies should not be abandoned, but they may be included after critical appraisal, empirical study, and methodologic evaluation (29). Oftentimes, combining data from several smaller observational studies may be an efficient, effective, and perhaps the only means of reaching a conclusion (41). The challenge lies in developing a methodology for evaluating these observational studies and deciding whether to include a particular study. During the evaluation

period, the observational studies were scrutinized with the same scoring system for bias as randomized controlled trials. Further, we analyzed the data with a random-effects analysis to accommodate for heterogeneity. One other approach to reduce heterogeneity is to remove primary studies selectively from consideration, but this method opens the door for other bias. If removal of studies from the analysis is not based on biological and clinical differences of study design or specific interventions, removal may shift the weight of the evidence inappropriately on the measured outcome.

Although our approach was not totally free of problems, it contained other safeguards against methodologic bias that plagued earlier meta-analyses. Our scoring system excluded studies during the evaluation phase with large numbers of individual dropouts after randomization, which was different from other meta-analyses that included these types of studies (42). The individuals who dropped out may differ systematically from those who stayed in, and, if studies with excessive dropouts are included, then the meta-analysis may be influenced by confounding bias. Not all the studies included in prior meta-analyses (even randomized trials) examined the distribution of age even though it is known to be a confounder, and some studies demonstrated detection bias because they included individuals with subclinical varicoceles. The five studies in the present meta-analysis all had men with palpable varicoceles only, including Grasso et al. (14), who studied men with ultrasound and a scoring system that included small, palpable, grade I lesions. Although it takes careful planning and a greater work effort, it seems important to evaluate for all of these types of bias during the evaluation phase to include the most reliable data in the meta-analysis.

With regard to spontaneous pregnancy outcome, some studies found that there is no difference in the odds of pregnancy for men who underwent varicocelectomy in comparison with those who did not. However, this lack of difference may be due to the fact that the researcher was not seeking to record pregnancy as a main outcome variable. If large studies are included in a meta-analysis with only partial pregnancy data, they may be given more weight, despite that the study did not aim to measure the odds of pregnancy. This would cause the overall conclusion to be weighted toward no effect. If the patients' cases had been followed up thoroughly, there might have been a different observed effect of treatment on the outcome.

In our meta-analysis, we used an approach that was consistent with the guidelines for meta-analyses of the Potsdam Collaboration (29). We included only studies that had spontaneous pregnancy data as an intended outcome. We evaluated five studies that led us to conclude that a surgical varicocelectomy improved spontaneous pregnancy outcome on the basis of the odds ratio and the number needed to treat. Furthermore, even after removal of the figures of the most favorable study (1), the number needed to treat results from the remaining four studies seemed comparable to those of the original five.

In a side study, we found that the pregnancy results after varicocelectomy were usually associated with the improvement in sperm density. The four studies with improved pregnancy rates all reported statistically significant increases in postoperative sperm density, whereas the one study that reported no improved pregnancy rates had no improvement in the postoperative sperm density. Presently, these findings may have increased clinical relevance, because recent reports have linked sperm density to fertility in other situations. For example, a study of fertile and infertile populations reported that the mean sperm densities for these groups were 19.5 versus 8.5 $10^6/\text{mL}$, respectively ($P < .001$) (43). Another study reported that doubling the sperm concentration, for example, from 4 to $8 \times 10^6/\text{mL}$, increased the monthly conception rate by a factor of 2.8, and doubling the concentration from 8 to $16 \times 10^6/\text{mL}$ or from 16 to $32 \times 10^6/\text{mL}$ increased fecundability by factors of 1.34 and 1.32, respectively (44). Still other studies showed that the odds ratio for subfertility was 5.6 (3.3–8.3) for those men with sperm densities $< 13.5 \times 10^6/\text{mL}$, compared with an odds ratio of 1.3 (1.2–2.2) for men with sperm densities between 13.5 and $48 \times 10^6/\text{mL}$ (45). Thus, the measurement of sperm density continues to be important in the evaluation of male factor infertility. However, there is usually great variability in the parameters from consecutive semen studies, and a panel of at least three preoperative and three postoperative semen analyses is needed to avoid the statistical phenomenon of regression toward the mean (3). Although semen data were not included in the present manuscript, future varicocele studies probably should include this type of panel to evaluate both patients and controls.

Recently, other new molecular and genetic markers have been used to stratify patients with varicocele (46, 47). For example, some studies have documented increased DNA damage to the sperm in the semen of infertile men with varicoceles; others demonstrate the presence of oxidative stress (48, 49). In still other studies, there was no improvement in semen parameters after varicocelectomy among men with Y-chromosome microdeletions or abnormal karyotypes (50), and reduced pregnancy outcomes after varicocelectomy among men with increased testis tissue cadmium, and microdeletions in the sequence of the L-type, voltage-dependent calcium channel (51). Thus, the presence or absence of these markers may explain why some men with varicoceles are fertile and others do not improve after varicocelectomy. Furthermore, future studies in men with varicoceles may be more selective by stratification with these markers. This approach may identify those patients with a realistic opportunity to benefit from these procedures versus those in whom varicocelectomy is likely to fail on a molecular/genetic basis.

CONCLUSION

On the basis of the data from current literature, we conclude from this meta-analysis that a surgical varicocelectomy is an effective treatment for improving the spontaneous pregnancy rate for couples with an infertile male partner who has low semen parameters and a palpable varicocele. In the future,

randomized controlled trials should include stratification with a panel of semen analyses and molecular/genetic markers. Furthermore, the control groups should be offered some meaningful treatment such as IVF to avoid unfair conditions for participation in a research study.

Acknowledgments: Di He, B.S. (summer student, volunteer), provided statistical assistance. The authors would like to thank Andrew C. Novick, M.D., Chairman, Glickman Urological Institute, Cleveland Clinic, for his encouragement and support for research.

REFERENCES

- Madgar I, Weissenberg R, Lunenfeld B, Karasik A, Goldwasser B. Controlled trial of high spermatic vein ligation for varicocele in infertile men. *Fertil Steril* 1995;63:120–4.
- Schlesinger MH, Wilets IF, Nagler HM. Treatment outcome after varicocelectomy. A critical analysis. *Urol Clin North Am* 1994;21:517–29.
- Marmar JL, Kim Y. Subinguinal microsurgical varicocelectomy: a technical critique and statistical analysis of semen and pregnancy data. *J Urol* 1994;152:1127–32.
- Onozawa M, Endo F, Suetomi T, Takeshima H, Akaza H. Clinical study of varicocele: statistical analysis and the results of long-term follow-up. *Int J Urol* 2002;9:455–61.
- Okuyama A, Fujisue H, Matsui T, Doi Y, Takeyama M, Nakamura N, et al. Surgical repair of varicocele: effective treatment for subfertile men in a controlled study. *Eur Urol* 1988;14:298–300.
- Cayan S, Kadioglu TC, Tefekli A, Kadioglu A, Tellaloglu S. Comparison of results and complications of high ligation surgery and microsurgical high inguinal varicocelectomy in the treatment of varicocele. *Urology* 2000;55:750–4.
- Goldstein M, Gilbert BR, Dicker AP, Dwosh J, Gnecco C. Microsurgical inguinal varicocelectomy with delivery of the testis: an artery and lymphatic sparing technique. *J Urol* 1992;148:1808–11.
- Sayfan J, Soffer Y, Orda R. Varicocele treatment: prospective randomized trial of 3 methods. *J Urol* 1992;148:1447–9.
- Segenreich E, Israilov SR, Shmueli J, Niv E, Servadio C. Correlation between semen parameters and retrograde flow into the pampiniform plexus before and after varicocelectomy. *Eur Urol* 1997;32:310–4.
- Kamischke A, Nieschlag E. Varicocele treatment in the light of evidence-based andrology. *Hum Reprod Update* 2001;7:65–9.
- Clinical guidelines: Fertility: assessment and treatment for people with fertility problems. National Collaborating Centre for Women's and Children's Health 2004;54–5.
- Evers JL, Collins JA. Surgery or embolisation for varicocele in subfertile men. *Cochrane Database Syst Rev* 2004;CD000479.
- Nilsson S, Edvinsson A, Nilsson B. Improvement of semen and pregnancy rate after ligation and division of the internal spermatic vein: fact or fiction? *Br J Urol* 1979;51:591–6.
- Grasso M, Lania C, Castelli M, Galli L, Franzoso F, Rigatti P. Low-grade left varicocele in patients over 30 years old: the effect of spermatic vein ligation on fertility. *BJU Int* 2000;85:305–7.
- Breznik R, Vlaisavljevic V, Borko E. Treatment of varicocele and male fertility. *Arch Androl* 1993;30:157–9.
- Rageth JC, Unger C, DaRugna D, Steffen R, Stucki D, Barone C, et al. Long-term results of varicocelectomy. *Urol Int* 1992;48:327–31.
- Krause W, Muller HH, Schafer H, Weidner W. Does treatment of varicocele improve male fertility? Results of the "Deutsche Varikozelenstudie," a multicentre study of 14 collaborating centres. *Andrologia* 2002;34:164–71.
- Jarow JP, Sharlip ID, Belker AM, Lipshultz LI, Sigman M, Thomas AJ, et al. Best practice policies for male infertility. *J Urol* 2002;167:2138–44.
- Sharlip ID, Jarow JP, Belker AM, Lipshultz LI, Sigman M, Thomas AJ, et al. Best practice policies for male infertility. *Fertil Steril* 2002;77:873–82.

20. Dohle GR, Colpi GM, Hargreave TB, Papp GK, Jungwirth A, Weidner W. EAU Guidelines on Male Infertility. *Eur Urol* 2005;48:703–11.
21. Williams JK. Understanding evidence-based medicine: a primer. *Am J Obstet Gynecol* 2001;185:275–8.
22. Templeton A. Varicocele and infertility. *Lancet* 2003;361:1838–9.
23. Marmar J, Benoff S. New scientific information related to varicoceles. *J Urol* 2003;170:2371–3.
24. Ficarra V, Cerruto MA, Ligouri G, Mazzano G, Minucci S, Tracia A, et al. Treatment of varicocele in subfertile men: The Cochrane review—a contrary opinion. *Eur Urol* 2006;49:258–63.
25. Yavetz H, Levy R, Papo J, Yogev L, Paz G, Jaffa AJ, et al. Efficacy of varicocele embolization versus ligation of the left internal spermatic vein for improved sperm quality. *Int J Androl* 1992;15:338–44.
26. Shlansky-Goldberg RD, VanArsdalen KN, Rutter CM, Soulen MC, Haskal ZJ, Baum RA, et al. Percutaneous varicocele embolization versus surgical ligation for the treatment of infertility: changes in seminal parameters and pregnancy outcomes. *J Vasc Interv Radiol* 1997;8:759–67.
27. Peipert JF, Phipps MG. Observational studies. *Clin Obstet Gynecol* 1998;41:235–44.
28. Norris SL, Atkins D. Challenges in using nonrandomized studies in systematic reviews of treatment interventions. *Ann Intern Med* 2005;142:1112–9.
29. Cook DJ, Sackett DL, Spitzer WO. Methodologic guidelines for systematic reviews of randomized control trials in health care from the Potsdam Consultation on Meta-Analysis. *J Clin Epidemiol* 1995;48:167–71.
30. Higgins JPT, Green S, editors. *Cochrane handbook for systematic reviews of interventions 4.2.5*. In: *The Cochrane Library*, 2005. Chichester: Wiley.
31. Bender R. Calculating confidence intervals for the number needed to treat. *Controlled Clin Trials* 2001;22:102–10.
32. Nieschlag E, Hertle L, Fishedick A, Abshagen K, Behre HM. Update on treatment of varicocele: counselling as effective as occlusion of the vena spermatica. *Hum Reprod* 1998;13:2147–50.
33. Thacker SB, Stroup DF, Peterson HB. Meta-analysis for the practicing obstetrician gynecologist. *Clin Obstet Gynecol* 1998;41:275–81.
34. Sacks HS, Berrier J, Reitman D, Ancona-Berk VA, Chalmers TC. Meta-analyses of randomized controlled trials. *N Engl J Med* 1987;316:450–5.
35. Egger M, Smith GD. Bias in location and selection of studies. *BMJ* 1998;316:61–6.
36. Berlin JA. Does blinding of readers affect the results of meta-analyses? University of Pennsylvania Meta-analysis Blinding Study Group. *Lancet* 1997;350:185–6.
37. Beck CT. The effects of postpartum depression on maternal-infant interaction: a meta-analysis. *Nurs Res* 1995;44:298–304.
38. Dennis LK, Snetselaar LG, Nothwehr FK, Stewart RE. Developing a scoring method for evaluating dietary methodology in reviews of epidemiologic studies. *J Am Diet Assoc* 2003;103:483–7.
39. Juni P, Witschi A, Bloch R, Egger M. The hazards of scoring the quality of clinical trials for meta-analysis. *JAMA* 1999;282:1054–60.
40. Comhaire F. Clinical andrology: from evidence-base to ethics. The “E” quintet in clinical andrology. *Hum Reprod* 2000;15:2067–71.
41. Stroup DF, Berlin JA, Morton SC, Olkin I, Williamson GD, Rennie D, et al. Meta-analysis of observational studies in epidemiology: a proposal for reporting. Meta-analysis of Observational Studies in Epidemiology (MOOSE) group. *JAMA* 2000;283:2008–12.
42. Evers JL, Collins JA. Assessment of efficacy of varicocele repair for male subfertility: a systematic review. *Lancet* 2003;361:1849–52.
43. Ombelet W, Bosmans E, Janssen M, Cox A, Vlasselaer J, Gyselaers W, et al. Semen parameters in a fertile versus subfertile population: a need for change in the interpretation of semen testing. *Hum Reprod* 1997;12:987–93.
44. Bonde JP, Ernst E, Jensen TK, Hjollund NH, Kolstad H, Henriksen TB, et al. Relation between semen quality and fertility: a population-based study of 430 first-pregnancy planners. *Lancet* 1998;352:1172–7.
45. Guzik DS, Overstreet JW, Factor-Litvak P, Brazil CK, Nakajima ST, Coutifaris C, et al. Sperm morphology, motility, and concentration in fertile and infertile men. *N Engl J Med* 2001;345:1388–93.
46. Benoff S, Gilbert BR. Varicocele and male infertility: part I. Preface. *Hum Reprod Update* 2001;7:47–54.
47. Marmar J. Varicocele and male infertility: part II. *Hum Reprod Update* 2001;7:461–742.
48. Saleh RA, Agarwal A, Sharma RK, Said TM, Sikka SC, Thomas AJ Jr. Evaluation of nuclear DNA damage in spermatozoa from infertile men with varicocele. *Fertil Steril* 2003;80:1431–6.
49. Zini A, Blumenfeld A, Libman J, Willis J. Beneficial effect of microsurgical varicocelectomy on human sperm DNA integrity. *Hum Reprod* 2005;20:1018–21.
50. Cayan S, Lee D, Black LD, Reijo Pera RA, Turek PJ. Response to varicocelectomy in oligospermic men with and without defined genetic infertility. *Urology* 2001;57:530–5.
51. Marmar JL, Benoff S. The safety of ultrasonically guided testis aspiration biopsies and efficacy of use to predict varicocelectomy outcome. *Hum Reprod* 2005;20:2279–88.

APPENDIX

Initial scoring sheet used for evaluating studies that included men with palpable varicoceles, at least one low semen parameter, and pregnancy data after varicocelectomies

Study number _____ Reviewer Initials _____

Selection/Follow-up _____ Total _____

From what, if any, underlying cohort is the study population derived?

- 3 From a geographical cohort
- 3 From a community
- 2 From a clinic population
- 1 Unable to answer

How were subjects recruited?

- 3 All cases in the population were included
- 2 Cases were recruited consecutively over a period of time
- 3 Cases were randomly selected
- 1 Unable to answer

Was there loss of follow-up or lack of participation greater than 10% of those sampled initially?

- 1 Yes
- 2 No
- 1 Unable to answer

Did the investigators restrict against participants based on infection, previous treatment, and female factor infertility or conditions related to ART outcome and sperm parameters?

- 3 Yes
- 2 No
- 1 Unable to answer

Confounding

Total _____

Was the time between the two follow-up periods short enough to allow for no confounding by age within subjects (under 2 years)?

- 3 Yes
- 1 No
- 1 Unable to answer

Did they evaluate and account for potential confounders that may vary over time?

ie, amount of follow-up time, season, smoking, alcohol consumption, original sperm count, time-varying exposures, etc.

- 1 No
- 2 Yes, but they do not adjust
- 3 Yes, and they adjust for them when necessary
- 1 Unable to answer

Did the investigators pre-specify the same procedures for analysis for before and after the intervention?

- 2 Yes
- 2 Not applicable
- 1 No
- 1 Unable to answer

Information/Detection Bias

Total _____

Was the method of follow-up the same before and after treatment?

- 3 Yes
- 2 No
- 1 Unable to answer

If blinding was possible, were those evaluating outcomes blinded to the patient's intervention/disease status?

- 2 Blinding was not possible
- 1 Blinding was possible but not done for all/some investigators
- 3 Blinding was performed
- 1 Unable to answer

Was the measurement of outcome(s) objective?

Objective meaning medical records or diagnostic test, not objective/subjective meaning recall, etc.

- 3 Yes
- 2 No
- 1 Unable to answer

Was ascertainment of outcome performed at the same location both before and after treatment?

- 4 Yes
- 2 No
- 1 Unable to answer

Other

Total _____

Does the study combine outcomes across groups with very heterogeneous histories/durations of infertility and across different interventions?

- 2 Yes, together

- 3 No
- 1 Unable to answer

Was severity/grade of varicocele evaluated both before and after the intervention?

- 3 Yes
- 2 No
- 1 Unable to answer

Did investigators use an established set of guidelines for semen analysis?

- 4 Yes
- 1 No
- 1 Unable to answer

Exclusion Criteria

Category	Maximum Score	Minimum Score	Include Score	Exclude Score
Selection	11	4	11-7	6-4
Confounding	8	3	8-5	4-3
Information	13	4	13-12	11-4
Other	10	3	10-8	7-3

- Any study will be excluded if 2 or more categories score in the “exclude range”.
- Any study will be re-reviewed if only 1 category scores in the “exclude range”.

Decreased Sperm DNA Fragmentation After Surgical Varicocelectomy is Associated With Increased Pregnancy Rate

Marij Smit,* Johannes C. Romijn, Mark F. Wildhagen, Joke L. M. Veldhoven, Robertus F. A. Weber† and Gert R. Dohle

From the Andrology Unit, Department of Urology and Trials and Research Coordination, Departments of Urology and Gynaecology (MFW), Erasmus Medical Center Rotterdam, Rotterdam, The Netherlands

Abbreviations and Acronyms

ART = assisted reproductive technique

DFI = DNA fragmentation index

FSH = follicle-stimulating hormone

IVF = in vitro fertilization

LH = luteinizing hormone

ROS = reactive oxygen species

SCSA = sperm chromatin structure assay

Submitted for publication May 13, 2009.

Study received institutional review board approval.

* Department of Urology, Erasmus Medical Center, P. O. Box 2040, 3000 CA Rotterdam, The Netherlands (telephone: 0031 10 463 23 45 or 0031 10 463 57 67; FAX: 0031 10 463 57 63; e-mail: m.smit.3@erasmusmc.nl).

† Deceased.

Purpose: We prospectively evaluated changes in sperm chromatin structure in infertile patients before and after surgical repair of varicocele, and the impact on the pregnancy rate.

Materials and Methods: Included in the study were 49 men with at least a 1-year history of infertility, a palpable varicocele and oligospermia. World Health Organization semen analysis and sperm DNA damage expressed as the DNA fragmentation index using the sperm chromatin structure assay were assessed preoperatively and postoperatively. Pregnancy (spontaneous and after assisted reproductive technique) was recorded 2 years after surgery.

Results: Mean sperm count, sperm concentration and sperm progressive motility improved significantly after varicocelectomy from 18.3×10^6 to 44.4×10^6 , 4.8×10^6 /ml to 14.3×10^6 /ml and 16.7% to 26.6%, respectively ($p < 0.001$). The DNA fragmentation index decreased significantly after surgery from 35.2% to 30.2% ($p = 0.019$). When the definition of greater than 50% improvement in sperm concentration after varicocelectomy was applied, 31 of 49 patients (63%) responded to varicocelectomy. After varicocelectomy 37% of the couples conceived spontaneously and 24% achieved pregnancy with assisted reproductive technique. The mean postoperative DNA fragmentation index was significantly higher in couples who did not conceive spontaneously or with assisted reproductive technique ($p = 0.033$).

Conclusions: After varicocelectomy sperm parameters significantly improved and sperm DNA fragmentation was significantly decreased. Low DNA fragmentation index values are associated with a higher pregnancy rate (spontaneous and with assisted reproductive technique). We suggest that varicocelectomy should be considered in infertile men with palpable varicocele, abnormal semen analysis and no major female factors.

Key Words: testis; fertility, male; varicocele; spermatozoa; DNA damage

VARICOCELE is a common abnormality, found in 12% of the adult male population and in 25% of men in infertile couples.¹ The exact pathophysiology of male infertility due to varicocele is still not clear and varicocele treatment remains controversial in clinical andrology. Although WHO data clearly indi-

cate that varicocele is associated with semen abnormalities, and decreased testicular volume and Leydig cell function,¹ it remains to be proved whether varicocele repair also restores male fertility potential.²

Two recent meta-analyses showed that surgical varicocelectomy signifi-

cantly improves sperm concentration and motility in infertile men with palpable varicocele and abnormal preoperative semen parameters,^{3,4} and increases the odds ratio of spontaneous pregnancy.⁴

A large body of evidence has accumulated to indicate that sperm DNA damage is increased in infertile men and high levels of damage are associated with a decreased pregnancy rate, including spontaneous pregnancy^{5,6} and pregnancy after ART.⁷ Several groups reported that varicocele is associated with increased sperm DNA damage.^{8,9} Since varicolectomy may improve sperm DNA damage in infertile men,^{10,11} we evaluated repair induced changes in sperm chromatin structure and correlated postoperative DNA damage with the pregnancy rate (spontaneous and after ART).

MATERIALS AND METHODS

Patients

A total of 52 men with at least a 1-year history of infertility, a palpable varicocele, oligospermia and normal or correctable female fertility were eligible for this pilot study from November 2003 to June 2006. Andrological examination included medical history, physical examination, testicular volume measurement with a Prader orchidometer, scrotal ultrasound, endocrine analysis of serum LH (normal 1.5 to 8.0 IU/l), FSH (normal 2.0 to 7.0 IU/l), testosterone (normal 10.0 to 30.0 nmol/l) and inhibin B (normal 150 to 400 ng/l), and semen analysis according to WHO guidelines.¹² Sperm DFI was assessed by SCSA.

A palpable varicocele was confirmed by scrotal ultrasound done using a Nemio™ 20 with a 12 Hz transducer equipped with color flow imaging when at least 1 scrotal vein had a maximum diameter of at least 3 mm and retrograde flow was observed at rest or after the Valsalva maneuver. Grade 1 varicocele was diagnosed when reflux was measured at less than 2 seconds, grade II when reflux lasted for more than 2 seconds and grade III when reflux was noted at spontaneous respiration.

Postoperative followup at 3 months to assess the effect of varicolectomy comprised WHO semen analysis, SCSA, scrotal ultrasound and endocrine evaluation. Patients served as their own controls since we compared the effect of varicocele repair on sperm quality with time. In 2 patients no preoperative semen sample was collected and 1 was lost to followup. A total of 49 couples were available for analysis. Since SCSA is incorporated in the standard evaluation of semen at our laboratory, medical ethical and institutional review board approval was not separately issued. In 2008 pregnancies ART, the pregnancy outcome and time to pregnancy were evaluated from patient records.

Sperm DNA Fragmentation Measurement

The SCSA was performed essentially as described by Evenson and Jost¹³ using a FACScan™ flow cytometer. Briefly, frozen samples were quickly thawed, diluted to a concentration of 1 to 2 × 10⁶ sperm cells per ml, exposed to acid detergent solution and stained with acridine

orange. A similarly treated reference sample run before actual sample measurements was used to adjust the voltage gains of the flow cytometer FL3 and FL1 photomultipliers, which analyze red and green fluorescence, respectively. An aliquot of reference sample was run after every 5 to 10 samples. Voltage gains were readjusted when the fluorescent signal of the reference sample drifted. Data collection of the fluorescent pattern in 5,000 cells was done 3 minutes after acid treatment. Debris, bacteria and leukocytes were gated out during acquisition, as recommended by Evenson and Jost. The extent of DNA damage is expressed as the DFI, reflecting the ratio of red to total fluorescence. CellQuest™ Pro and WinList™ software were used to calculate the DFI of each sample. Each sperm sample was measured in duplicate and the mean of the results were used for analysis.

Statistical Analysis

Statistical analysis was performed using SPSS® 15.0. All results are expressed as the mean ± SD. The 1-sample Kolmogorov-Smirnov test was used to test for normality. Nonnormal distributed parameters (paired t test, total sperm count and sperm concentration) were logarithmically transformed to obtain normally distributed data. Differences between preoperative and postoperative semen variables were analyzed with the paired samples Student t test. Correlations were calculated using Spearman's rank correlation coefficient.

All patients were divided into 2 groups based on the spermatogenic response to varicocele repair. Responders were defined as patients in whom the sperm concentration increased by 50% or more after varicolectomy.^{14,15} Preoperative differences in continuous variables between the 2 consequent data sets were analyzed with the t test and the chi-square test was used for dichotomous variables to identify possible predictors of the response to surgery. All variables at a maximum of p = 0.2 were used in a backward multivariate logistic regression analysis model to evaluate determinants of surgical response. Univariate analysis using ANOVA and the t test was done to evaluate possible predictors of spontaneous and ART assisted pregnancies.

RESULTS

The mean age of male patients was 34 ± 6.9 years and mean partner age at varicocele repair was 30 ± 4.9 years. Included in analysis were 41 men diagnosed with primary infertility and 8 with secondary infertility. The mean duration of infertility was 2.7 ± 1.6 years.

Six female partners were diagnosed with irregular cycles, of whom 3 were successfully treated with clomiphene citrate and 2 couples were eventually treated with IVF. In 1 female who remained anovular despite treatment endometriosis was diagnosed during diagnostic laparoscopy.

Medical history revealed that 10 of 49 patients were smokers, 1 was a farmer who was periodically exposed to pesticides, 4 were treated for cryptorchidism at childhood, which was unilateral and bilateral

in 2 each, 5 had a history of urogenital infection, 4 underwent hernia repair in childhood and 1 was treated with urethrotomy for a urethral stricture.

A left grade I varicocele was found in 16 patients, grades II and III varicoceles were present in 15 and 13, respectively, and 5 had bilateral varicocele. Left high inguinal spermatic vein ligation¹⁶ was performed in 36 men and microsurgical varicocelectomy¹⁷ was done in 8. All bilateral varicoceles were treated with bilateral high inguinal ligation. Because only 1 urologist (GRD) at our clinic had mastered microsurgical varicocelectomy, this technique was not exclusively performed in 2003 to 2006. In 4 of 49 patients (8%) recurrent varicocele diagnosed during followup was treated with high inguinal ligation for bilateral (2), and grades I (1) and III (1) varicocele.

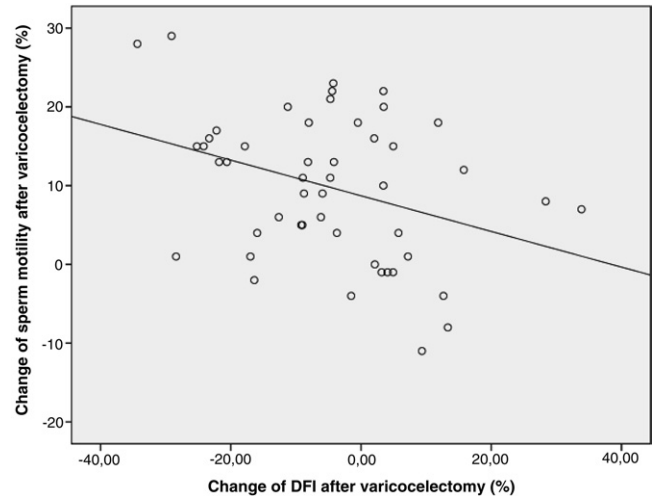
Mean sperm count, concentration and progressive motility improved significantly after varicocelectomy but DFI significantly decreased after surgery (table 1). A significant negative relationship was detected between the change in DFI and the change in sperm motility after varicocele surgery (see figure).

When defining a positive response as greater than a 50% improvement in sperm concentration after varicocelectomy, 31 of 49 patients (63%) were responders. Analysis of SCSA results in the responder group showed a significant decrease in DFI after surgery (table 2). Preoperative reproductive hormones were not significantly different in the responder and nonresponder groups. However, LH and FSH increased significantly after varicocele treatment in the nonresponder group.

On univariate analysis only the log preoperative sperm concentration was associated with a positive surgical outcome ($p = 0.039$). Also, when continuous and dichotomous preoperative variables at a maximum of $p = 0.2$ were reviewed, log preoperative sperm count ($p = 0.097$) and preoperative LH ($p = 0.085$) applied and were entered in a backward multivariate logistic regression analysis model. Only log preoperative sperm concentration predicted a positive surgical outcome (OR 0.229, $p = 0.044$). This means that a lower preoperative sperm concentra-

Table 1. Sperm parameters and DFI before and after varicocelectomy

Parameter	Mean \pm SD Preop	Mean \pm SD Postop	p Value
Total sperm count ($\times 10^6$)	18.3 \pm 23.3	44.4 \pm 48.0	<0.001
Sperm concentration ($\times 10^6$ /ml)	4.8 \pm 4.7	14.3 \pm 14.3	<0.001
% Progressive motility	16.7 \pm 12.5	26.6 \pm 15.7	<0.001
% Normal morphology	2.5 \pm 2.1	2.8 \pm 1.9	0.188
% DFI	35.2 \pm 13.1	30.2 \pm 14.7	0.019



DFI change after varicocelectomy and subsequent sperm motility change (Spearman correlation $r = -0.312$, $p = 0.029$).

tion was associated with a positive response to surgery.

After varicocelectomy 18 of the 49 couples (37%) conceived spontaneously within a mean of 7.2 ± 6.7 months. In 12 of the 49 couples (24%) spontaneous pregnancy was not achieved and they decided not to proceed with ART. A pregnancy rate of 22% (11 of 49 couples) was achieved after ART within a mean of 14.6 ± 7.7 months after varicocele repair. Intrauterine insemination, IVF and intracytoplasmic sperm injection were performed in 8, 4 and 7 couples, respectively. Nine of the 19 couples (42%) in whom ART was used failed to conceive after 3 intracytoplasmic sperm injection cycles in 5, a poor response after IVF in 1 and 6 intrauterine insemination cycles in 2. The mean postoperative DFI was significantly different in couples who could not conceive spontaneously or with ART ($p = 0.033$, table 3). The mean DFI was significantly increased in couples

Table 2. DFI and endocrine parameters in responders and nonresponders

	Mean \pm SD Preop	Mean \pm SD Postop	p Value
31 Responders:			
% DFI	35.3 \pm 14.3	28.6 \pm 14.7	0.009
LH (IU/l)	3.9 \pm 1.8	4.3 \pm 1.8	0.436
FSH (IU/l)	8.0 \pm 6.2	9.2 \pm 5.6	0.508
Testosterone (nmol/l)	14.9 \pm 4.8	15.0 \pm 4.3	0.084
Inhibin B (ng/l)	126.7 \pm 48.5	126.2 \pm 65.3	0.102
18 Nonresponders:			
% DFI	35.0 \pm 11.2	33.0 \pm 14.8	0.602
LH (IU/l)	3.0 \pm 1.3	4.0 \pm 1.6	0.018
FSH (IU/l)	6.6 \pm 2.8	7.6 \pm 3.6	0.006
Testosterone (nmol/l)	14.7 \pm 5.2	15.3 \pm 4.5	0.390
Inhibin B (ng/l)	140.7 \pm 60.1	133.8 \pm 63.8	0.224

Table 3. Postoperative DFI in 4 pregnancy groups

	Mean \pm SD % DFI
Spontaneous pregnancy	30.1 \pm 12.2
Failure to conceive spontaneously	37.5 \pm 13.3
Pregnancy after ART	21.3 \pm 14.7
Failure to conceive after ART	36.9 \pm 15.6

with failure to conceive after ART compared to couples that achieved pregnancy with ART ($p = 0.041$). DFI was also increased in couples who failed to conceive spontaneously vs couples who conceived after ART ($p = 0.014$). Overall the mean DFI was significantly lower in couples who conceived spontaneously or with ART compared to that in couples with failure ($26.6\% \pm 13.7$ vs $37.3\% \pm 13.9$, $p = 0.013$).

DISCUSSION

In accordance with previous studies we found a significant increase in postoperative sperm count, concentration and progressive motility after surgical repair of palpable varicoceles in patients with abnormal semen parameters.^{3,4} Since sperm quality expressed as WHO semen parameters is subject to large biological variation and semen analysis is hampered by high interobserver and intra-observer variation,¹⁸ it was suggested that this variability may explain the apparent differences between preoperative and postoperative semen samples after varicocele repair. Sperm DNA fragmentation provides additional information about sperm quality and the ability of a couple to conceive.⁵ SCSA is a validated method for studying sperm chromatin integrity.¹⁹ We previously reported that DFI biological variation is much lower than that of conventional semen parameters and DFI variability is not increased by varicocele.²⁰

Not all men with a varicocele have improved sperm parameters after varicocelectomy and a 50% to 70% success rate was reported.¹⁵ We applied a strict definition of greater than 50% improvement in sperm concentration to identify clinically relevant responders to surgery^{14,15} and found that 63% of our patients responded to varicocele repair. In this pilot study DFI decreased significantly after varicocelectomy in the whole study population and in the responder group, suggesting that varicocele repair is effective for decreasing DFI in most patients. In the nonresponder group no clear effect on sperm DNA damage was observed but the lower number of patients in that group may explain this. A limitation of our pilot study is that for practical reasons only 1 postoperative semen sample was used.

Although lower postoperative DFI was associated with a higher pregnancy rate, postoperative mean

DFI was relatively high in the spontaneous pregnancy group at 30.2% when considering that fertility is reported to be limited when DFI exceeds 30%.¹⁹ Our preliminary results require validation in a larger study of sperm DNA damage in multiple postoperative semen samples.

In the search for molecular mechanisms associated with varicocele related infertility recent research has focused on ROS and apoptosis markers in testicular tissue, and semen in varicocele cases.²¹ Oxidative stress and testicular apoptosis are well documented causes of increased sperm DNA fragmentation. Varicocele is associated with increased ROS production in spermatozoa and decreased antioxidant capacity in semen.²² ROS was decreased after varicocele repair¹¹ even in patients in whom semen quality did not improve after varicocelectomy.²³ Sperm DNA damage may be a late effect of excessive ROS, which may explain why not all infertile patients in our study showed a decrease in sperm DNA damage after varicocele repair.

Germ cell apoptosis is an inherent process in spermatogenesis but it is clearly up-regulated in a number of stress conditions, such as varicocele.²⁴ Patients who responded to varicocelectomy had significant lower apoptosis levels in testicular biopsies.¹⁴

Because idiopathic male infertility and varicocele are linked to increased ROS, increased apoptosis and increased sperm DNA damage, one could also hypothesize that these phenomena are merely hypospermatogenesis symptoms. Abnormalities associated with hypospermatogenesis, such as improper protamination, aberrant apoptosis and the release of abnormal spermatozoa with immature chromatin status, may contribute to the generation of high ROS levels.²⁵ Most likely a combination of mechanisms is involved in the etiology of defective spermatogenesis in patients with a varicocele. This may be an explanation of the heterogeneous clinical presentation in men with a varicocele and the variable response to varicocelectomy.

Perhaps our population of treated patients was too heterogeneous to attribute postoperative effects only to varicocele repair. However, our patient population reflects real life practice, in which many infertility patients and their partners have multiple defects that may explain the failure to conceive. According to the second hit hypothesis introduced by Marmar, "Varicocele is a secondary opportunistic lesion that contributes to infertility, the underlying cause being genetic or epigenetic factors, expressed in both testes."²¹ Our finding that LH and FSH were significantly increased after surgery in the nonresponder group may indicate that in these patients more predominant, ongoing causes of hyposper-

matogenesis and sperm DNA damage other than varicocele led to infertility.

Recently Cayan et al reported a 38% spontaneous pregnancy rate in a meta-analysis of the best surgical technique in a Palomo series and a 42% rate in a microsurgical varicocelectomy series.²⁶ Agarwal et al previously noted no differences in sperm quality improvement after microsurgical varicocelectomy or high inguinal ligation.³ Although in our study the number of patients treated with microsurgical varicocele repair was small, the spontaneous pregnancy outcome was not related to surgical technique. Microsurgical varicocele treatment seems to be the best technique with a higher spontaneous pregnancy rate and lower postoperative recurrence. Also, it is recommended by the American Urological Association best practice policy group.²⁷

Ficarra et al reviewed randomized, controlled trials of varicocele repair and found a significant increase in the pregnancy rate in patients who did vs did not

undergo varicocele treatment (36% vs 20%).²⁸ Marmar et al reported a 33% pregnancy rate in patients treated with surgical varicocelectomy and a 16% rate in controls with no surgery.⁴ These reported pregnancy rates are comparable to the 37% spontaneous pregnancy rate after varicocelectomy in our series. Couples with lower sperm DNA damage who do not achieve natural pregnancy after varicocele treatment have better results with ART.

CONCLUSIONS

Varicocelectomy can restore spermatogenesis, as reflected by improved sperm parameters and a significant decrease in sperm DNA fragmentation. Since lower DFI was associated with a higher pregnancy rate (spontaneous and after ART), we suggest that varicocelectomy should be considered in infertile men with a palpable varicocele, abnormal semen analysis and no major female factors.

REFERENCES

1. The influence of varicocele on parameters of fertility in a large group of men presenting to infertility clinics. World Health Organization. *Fertil Steril* 1992; **57**: 1289.
2. Evers JL and Collins JA: Assessment of efficacy of varicocele repair for male subfertility: a systematic review. *Lancet* 2003; **361**: 1849.
3. Agarwal A, Deepinder F, Cocuzza M et al: Efficacy of varicocelectomy in improving semen parameters: new meta-analytical approach. *Urology* 2007; **70**: 532.
4. Marmar JL, Agarwal A, Prabakaran S et al: Re-assessing the value of varicocelectomy as a treatment for male subfertility with a new meta-analysis. *Fertil Steril* 2007; **88**: 639.
5. Spano M, Bonde JP, Hjøllund HI et al: Sperm chromatin damage impairs human fertility. The Danish First Pregnancy Planner Study Team. *Fertil Steril* 2000; **73**: 43.
6. Evenson DP, Jost LK, Marshall D et al: Utility of the sperm chromatin structure assay as a diagnostic and prognostic tool in the human fertility clinic. *Hum Reprod* 1999; **14**: 1039.
7. Bungum M, Humaidan P, Spano M et al: The predictive value of sperm chromatin structure assay (SCSA) parameters for the outcome of intrauterine insemination, IVF and ICSI. *Hum Reprod* 2004; **19**: 1401.
8. Saleh RA, Agarwal A, Sharma RK et al: Evaluation of nuclear DNA damage in spermatozoa from infertile men with varicocele. *Fertil Steril* 2003; **80**: 1431.
9. Blumer CG, Fariello RM, Restelli AE et al: Sperm nuclear DNA fragmentation and mitochondrial activity in men with varicocele. *Fertil Steril* 2008; **90**: 1716.
10. Zini A, Blumenfeld A, Libman J et al: Beneficial effect of microsurgical varicocelectomy on human sperm DNA integrity. *Hum Reprod* 2005; **20**: 1018.
11. Hurtado de Catalfo GE, Ranieri-Casilla A, Marra FA et al: Oxidative stress biomarkers and hormonal profile in human patients undergoing varicocelectomy. *Int J Androl* 2007; **30**: 519.
12. WHO Laboratory Manual for the Examination of Human Semen and Sperm-Cervical Mucus Interaction, 4th ed. Cambridge, United Kingdom: Cambridge University Press 1999.
13. Evenson D and Jost L: Sperm chromatin structure assay is useful for fertility assessment. *Methods Cell Sci* 2000; **22**: 169.
14. Benoff SH, Millan C, Hurley IR et al: Bilateral increased apoptosis and bilateral accumulation of cadmium in infertile men with left varicocele. *Hum Reprod* 2004; **19**: 616.
15. Cayan S, Erdemir F, Ozbey I et al: Can varicocelectomy significantly change the way couples use assisted reproductive technologies? *J Urol* 2002; **167**: 1749.
16. Palomo A: Radical cure of varicocele by a new technique: preliminary report. *J Urol* 1949; **61**: 604.
17. Goldstein M, Gilbert BR, Dicker AP et al: Microsurgical inguinal varicocelectomy with delivery of the testis: an artery and lymphatic sparing technique. *J Urol* 1992; **148**: 1808.
18. Alvarez C, Castilla JA, Martinez L et al: Biological variation of seminal parameters in healthy subjects. *Hum Reprod* 2003; **18**: 2082.
19. Evenson DP, Larson KL and Jost LK: Sperm chromatin structure assay: its clinical use for detecting sperm DNA fragmentation in male infertility and comparisons with other techniques. *J Androl* 2002; **23**: 25.
20. Smit M, Dohle GR, Hop WC et al: Clinical correlates of the biological variation of sperm DNA fragmentation in infertile men attending an andrology outpatient clinic. *Int J Androl* 2007; **30**: 48.
21. Marmar JL: The pathophysiology of varicoceles in the light of current molecular and genetic information. *Hum Reprod Update* 2001; **7**: 461.
22. Hendin BN, Kolettis PN, Sharma RK et al: Varicocele is associated with elevated spermatozoal reactive oxygen species production and diminished seminal plasma antioxidant capacity. *J Urol* 1999; **161**: 1831.
23. Chen SS, Huang WJ, Chang LS et al: Attenuation of oxidative stress after varicocelectomy in subfertile patients with varicocele. *J Urol* 2008; **179**: 639.
24. Baccetti B, Collodel G and Piomboni P: Apoptosis in human ejaculated sperm cells (notulae seminologicae 9). *J Submicrosc Cytol Pathol* 1996; **28**: 587.
25. Gil-Guzman E, Ollero M, Lopez MC et al: Differential production of reactive oxygen species by subsets of human spermatozoa at different stages of maturation. *Hum Reprod* 2001; **16**: 1922.
26. Cayan S, Shavakhov S and Kadioglu A: Treatment of palpable varicocele in infertile men: a meta-analysis to define the best technique. *J Androl* 2009; **30**: 33.
27. Jarow JP, Sharlip ID, Belker AM et al: Best practice policies for male infertility. *J Urol* 2002; **167**: 2138.
28. Ficarra V, Cerruto MA, Liguori G et al: Treatment of varicocele in subfertile men: The Cochrane Review—a contrary opinion. *Eur Urol* 2006; **49**: 258.

Clinical Outcome of Intracytoplasmic Sperm Injection in Infertile Men With Treated and Untreated Clinical Varicocele

Sandro C. Esteves,* Fernanda V. Oliveira and Ricardo P. Bertolla

From the ANDROFERT, Center for Male Reproduction and Division of Urology, Department of Surgery, Human Reproduction Section, São Paulo Federal University, São Paulo, Brazil

Abbreviations and Acronyms

2PN = 2 pronuclei

ART = assisted reproductive technology

ICSI = intracytoplasmic sperm injection

IVF = in vitro fertilization

IUI = intrauterine insemination

Submitted for publication December 30, 2009.
Study received institutional review board approval.

* Correspondence: ANDROFERT, Center for Male Reproduction, 13075-460 Campinas, São Paulo, Brazil (telephone: +55 19 32958877; FAX: +55 1932946992; e-mail: s.esteves@androfert.com.br).

Purpose: We evaluated the impact of varicocelectomy on intracytoplasmic sperm injection outcomes in infertile men with clinical varicocele.

Materials and Methods: We studied 242 infertile men with a history of clinical varicocele who underwent intracytoplasmic sperm injection. Of the men 80 underwent prior subinguinal microsurgical varicocelectomy (treated group 1) and 162 had any grade of clinical varicocele (untreated group 2) at sperm injection. We compared semen analysis results before and after varicocelectomy, and the sperm injection procedure outcomes. Mean time from surgery to sperm injection was 6.2 months. Logistic regression was done to verify whether varicocelectomy influenced the odds of clinical pregnancy, live birth and miscarriage.

Results: We noted an improved total number of motile sperm (6.7×10^6 vs 15.4×10^6 , $p < 0.01$) and a decreased sperm defect score (2.2 vs 1.9, $p = 0.01$) after vs before varicocele repair. The clinical pregnancy (60.0% vs 45.0%, $p = 0.04$) and live birth (46.2% vs 31.4%, $p = 0.03$) rates after the sperm injection procedure were higher in the treated than in the untreated group. The chance of achieving clinical pregnancy (OR 1.82; 95% CI 1.06–3.15) and live birth (OR 1.87, 95% CI 1.08–3.25) by the sperm injection procedure were significantly increased while the chance of miscarriage was decreased (OR 0.433, 95% CI 0.22–0.84) after varicocele was treated.

Conclusions: Results suggest that varicocelectomy improves clinical pregnancy and live birth rates by intracytoplasmic sperm injection in infertile couples in which the male partner has clinical varicocele. The chance of miscarriage may be decreased if varicocele is treated before assisted reproduction.

Key Words: testis; infertility, male; sperm injections, intracytoplasmic; varicocele; abortion, spontaneous

THE complaint of infertility is common in the urological office. Approximately 8% of men of reproductive age seek medical assistance for fertility related problems, of whom 1% to 10% have conditions that compromise reproductive potential, including varicocele in 35%.¹ Several studies show that surgical treatment for clinical varicoceles is highly effective to decrease seminal oxidative stress, increase seminal antioxidants, and improve sperm qual-

ity and the percent of spermatozoa with intact DNA.^{2–4} A recent meta-analysis of varicocelectomy demonstrated the benefit of treating clinical varicocele in infertile men with abnormal semen analysis.⁵ In that study the unassisted pregnancy rate was significantly higher after varicocelectomy than in patients without surgery (33% vs 15.5%). The chance of spontaneous conception was 2.8 times higher in the varicocelectomy group

than in the patients who received no treatment or medication.

The benefit of repairing clinical varicocele in infertile men undergoing assisted conception is unclear. To date few studies have been published on this topic. In a small series the IUI success rate was higher in patients with treated varicocele.⁶ In a larger cohort of men Cayan et al reported that surgical repair improved semen parameters in about half and, thus, they suggested that varicocelectomy may rescue a number of couples from complex ART.⁷ To our knowledge it is still unknown whether varicocelectomy may improve the outcomes of invasive ART, such as IVF associated with ICSI. In clinical practice many patients with clinical varicocele and impaired sperm function are referred to ICSI without treatment due to the general belief that ICSI is highly successful independent of the cause of male infertility. We compared ICSI clinical and laboratory outcomes in infertile men with treated and untreated clinical varicocele.

MATERIALS AND METHODS

We reviewed the charts of all infertile men with clinical varicocele who underwent ICSI from January 2002 to July 2008. Varicocele was identified at physical examination and graded with the patient standing as large—grade 3 and visible, moderate—grade 2 and visible with the Valsalva maneuver, and small—grade 1 and palpable with the Valsalva maneuver. Only men with a complete infertility evaluation, including history, physical examination showing a clinical unilateral or bilateral varicocele, at least 2 semen analyses, hormone profile and genetic screening as appropriate were included in study.

Testicular volume was estimated with a Prader orchidometer. The hormonal profile included serum testosterone and follicle-stimulating hormone. Patients with a history of cryptorchidism, testicular trauma, orchitis, systemic or hormonal dysfunction and genetic abnormalities were excluded from study as well as those with azoospermia/cryptozoospermia and ICSI cycles involving egg donation.

A total of 242 men were included in analysis and grouped by varicocele repair history, including group 1—80 with prior successful varicocelectomy, defined as absent palpable varicocele, and group 2—162 with any grade of clinical varicocele at ICSI. Signed informed consent was obtained from patients to use clinical and laboratory data for analysis with guarantees of confidentiality. The study was approved by our institutional review board.

Indications for ICSI were in accordance with the guidelines of the II Brazilian Consensus of Male Infertility even if the indication of IVF was a female factor.⁸ Only couples with primary infertility and the first ICSI cycle of each patient were included in study. No patients in the untreated or treated group underwent IUI before ICSI because they did not meet institutional criteria for this type of ART. In group 1 mean time from varicocelectomy to ICSI was 6.2 months (range 4 to 13). In group 2 mean time

from the first appointment of the couple to ICSI was 4.2 months (range 3 to 15).

In the treated group patients underwent subinguinal microsurgical varicocelectomy on an outpatient basis, as previously described.^{4,9} Postoperative semen analysis was done at 3-month intervals. At least 2 semen analyses were obtained in each patient and evaluated by WHO criteria.¹⁰ Sperm parameters below normal values, ie sperm count less than $20 \times 10^6/\text{ml}$ (oligozoospermia), progressive motility less than 50% (asthenozoospermia) and strict morphology less than 9% (teratozoospermia), were considered sperm defects. A score of 1 was assigned to each defect and the sum of the defects was scored. Maximum and minimum possible sperm defect scores were 3—oligoasthenoteratozoospermia and 0—no defects, respectively. Multiple semen analysis results in an individual were pooled. Mean values were calculated for each seminal parameter and used for statistical purposes.

Ovarian stimulation was done using a long down-regulation gonadotropin-releasing hormone agonist protocol, followed by the administration of human menopausal gonadotropin or recombinant human follicle-stimulating hormone.¹¹ Human chorionic gonadotropin was administered when 2 or more ovarian follicles achieved a mean diameter of 18 mm. Oocyte retrieval, sperm processing and ICSI were done in clean room environments.^{11,12} Briefly, transvaginal ultrasound guided oocyte retrieval was performed 34 to 36 hours after human chorionic gonadotropin administration. ICSI was done for all metaphase II oocytes. Sperm samples were obtained by masturbation and processed by the 2-layer discontinuous colloidal gradient.¹³ Fertilization was considered normal when oocytes with 2PN and 2 polar bodies were seen 16 to 18 hours after ICSI. Fertilized oocytes were cultured until embryo transfer to the uterine cavity, which was guided by abdominal ultrasound on day 3 day of embryo culture. Embryos were graded morphologically using a light inverted microscope 48 and 72 hours after ICSI. High quality embryos had 3 or 4 and 7 or 8 symmetrical blastomeres on days 2 and 3 of culture, respectively, with no multinucleation, grade I or II fragmentation, or zona pellucida abnormalities.¹⁴ Clinical pregnancy was confirmed by a gestational sac with an embryo showing cardiac activity on ultrasound at weeks 5 to 6. Miscarriage was considered when nonviable clinical pregnancy was noted on ultrasound followup.

Qualitative variables are expressed as the number and percent. Quantitative variables are shown as the mean \pm SD. We applied the Kolmogorov-Smirnov test to assess the normal distribution by numerical variables. The Student *t* test was used to compare quantitative variables and the Pearson chi-square test was used to compare ICSI outcomes between the groups. We performed logistic regression analysis to verify whether varicocele repair increased the odds of clinical pregnancy and live birth or decreased the odds of miscarriage with $p < 0.05$ considered significant. All statistical data were processed with SPSS®, version 13.0.

RESULTS

From January 2002 to July 2008 at our institution 476 couples, in whom the male partner had a history of varicocele, underwent ICSI. Of these men 242

Table 1. Sperm parameter results in infertile men with treated and untreated clinical varicocele

	Mean \pm SD Group 1		p Value (paired Student's t test)	Mean \pm SD Group 2	p Value vs Group 1 (unpaired Student's t test)	
	Preop	Postop			Preop	Postop
Vol (ml)	3.1 \pm 1.2	3.0 \pm 1.2	0.85	3.5 \pm 1.7	0.42	0.30
Sperm count/ml ($\times 10^6$)	4.3 \pm 15.3	12.1 \pm 31.0	0.04	3.9 \pm 8.9	0.79	0.02
Total sperm count ($\times 10^6$)	14.1 \pm 23.8	34.9 \pm 61.3	0.02	10.6 \pm 14.6	0.15	<0.01
% Progressive motility	40.7 \pm 23.9	46.5 \pm 16.6	0.34	41.5 \pm 22.9	0.40	0.14
Total motile sperm count ($\times 10^6$)	6.7 \pm 5.5	15.4 \pm 9.1	<0.01	5.1 \pm 7.6	0.10	<0.01
% Strict morphology	5.5 \pm 5.9	5.7 \pm 4.4	0.89	5.6 \pm 3.9	0.64	0.78
Sperm defect score	2.2 \pm 0.5	1.9 \pm 0.7	0.01	2.2 \pm 0.8	0.92	<0.01

(50.8%) with treated or untreated clinical unilateral or bilateral varicocele met study inclusion criteria and were assessed.

The distribution of varicocele grades in groups 1 and 2 did not differ, including grades 1 to 3 in 18.8% and 20.4%, 43.7% and 40.1%, and 37.5% and 39.5% cases, respectively. The proportion of patients with bilateral varicocele in groups 1 and 2 was also similar (61.2% and 50.6%, respectively). Groups 1 and 2 were homogeneous in mean age of the patients (35.8 \pm 5.4 and 35.4 \pm 6.3 years) and female partners (32.6 \pm 4.4 and 32.2 \pm 4.3 years), serum hormones, combined left and right testicular volume (34.0 \pm 7.0 and 36.0 \pm 9.0 ml), history of infertility (3.7 \pm 7.1 and 4.2 \pm 6.8 years) and the proportion of females with a fertility associated problem (22.5% and 31.4%, respectively). Table 1 lists group 1 semen parameter results. Compared to before varicocele repair an improved total sperm count (14.1 $\times 10^6$ vs 34.9 $\times 10^6$, $p = 0.02$) and number of motile sperm (6.7 $\times 10^6$ vs 15.4 $\times 10^6$, $p < 0.01$), and a decreased sperm defect score (2.2 vs 1.9, $p = 0.01$) were observed after varicocele repair.

There was no statistically significant difference in the total number of retrieved and mature oocytes between the groups. The normal 2PN fertilization rate was significantly higher in the treated than in the untreated group (78% vs 66%, $p = 0.04$). There was no difference in the rate of high quality embryos between the groups. The mean number of transferred embryos was also similar. The clinical preg-

nancy rate after ICSI in the treated and untreated groups was 60.0% (48 of 80 cases) and 45.0% (73 of 162, $p = 0.04$). The miscarriage rate after achieving clinical pregnancy by ICSI did not differ between the groups (table 2). The live birth rate in the treated and untreated groups was 46.2% (37 of 80 cases) and 31.4% (51 of 162), respectively ($p = 0.03$). The chance of achieving clinical pregnancy (OR 1.82, 95% CI 1.06–3.15; $p = 0.03$) and live birth (OR 1.87, 95% CI 1.08–3.25; $p = 0.03$) by ICSI were increased but the chance of miscarriage after achieving pregnancy by ICSI was decreased (OR 0.433, 95% CI 0.22–0.84; $p = 0.01$) when varicocele was treated before assisted conception. In patients with varicocele repair the postoperative motile sperm count and fertilization rate by ICSI were significantly higher in those who achieved live birth compared to those in whom impregnation failed (table 3).

DISCUSSION

Varicocele, the most common cause of male infertility, is associated with decreased sperm quality.^{2,3} Spontaneous conception is significantly increased after varicolectomy in couples in whom the male partner has clinical varicocele and abnormal semen analysis.⁵ Although spontaneous pregnancy remains the litmus test to evaluate varicocele treatment success, many men with varicocele related infertility require ART due to severe sperm abnor-

Table 2. ICSI outcome in infertile couples in whom male partner had treated or untreated clinical varicocele

	Group 1	Group 2	p Value
Mean \pm SD No. oocytes:			
Retrieved	12.4 \pm 7.5	12.3 \pm 6.8	0.91 (unpaired Student's t test)
Metaphase II	10.2 \pm 6.4	10.0 \pm 5.5	0.46 (unpaired Student's t test)
Mean \pm SD % 2PN fertilization	78.0 \pm 20.0	66.0 \pm 22.0	0.04 (unpaired Student's t test)
Mean \pm SD % high quality embryo	47.0 \pm 29.0	49.9 \pm 29.0	0.76 (unpaired Student's t test)
Mean \pm SD No. embryos transferred	3.1 \pm 1.4	3.1 \pm 1.5	0.96 (unpaired Student's t test)
No. clinical pregnancy (%)	48 (60.0)	73 (45.0)	0.04 (Pearson's chi-square test)
No. miscarriage (%)	11 (22.9)	22 (30.1)	0.46 (Pearson's chi-square test)
No. live birth (%)	37 (46.2)	51 (31.4)	0.03 (Pearson's chi-square test)

Table 3. Semen analysis results and ICSI outcomes in 37 vs 43 infertile couples with vs without live birth in whom male partner underwent varicocele repair

	Mean \pm SD Live Birth	Mean \pm SD No Live Birth	p Value (unpaired Student's t test)
Vol (ml)	2.9 \pm 1.0	2.7 \pm 1.1	0.40
Sperm count ($\times 10^6$)	13.1 \pm 46.7	11.2 \pm 39.7	0.84
% Progressive motility	46.7 \pm 10.9	41.7 \pm 15.9	0.11
Total motile sperm count ($\times 10^6$)	17.9 \pm 4.7	12.6 \pm 6.4	<0.01
% Strict morphology	5.7 \pm 3.0	5.1 \pm 2.9	0.36
Sperm defect score	1.8 \pm 0.7	1.9 \pm 0.7	0.52
No. oocytes:			
Retrieved	12.4 \pm 7.4	12.3 \pm 7.4	0.95
Metaphase II	10.3 \pm 6.6	10.2 \pm 6.5	0.94
% 2PN fertilization	79.7 \pm 12.6	66.0 \pm 21.0	0.03
% High quality embryo	47.9 \pm 25.1	48.2 \pm 22.2	0.95
% Embryos transferred	3.3 \pm 1.5	3.2 \pm 1.4	0.75

malities and/or a significant problem affecting the female partner.

An indication for varicocele repair before IVF/ICSI is unusual but in certain cases varicocele treatment should be considered. Men with nonobstructive azoospermia may experience restored sperm to the ejaculate after repair of clinical varicocele.⁴ Although sperm restoration is minimal, it carries the possibility of IVF/ICSI without the need for sperm retrieval techniques. In patients who are still azoospermic after varicocelectomy the sperm retrieval rate using testicular microdissection sperm extraction increases and, as a result, so does the chance of the couple for pregnancy.¹⁵ Varicocele repair may enable some couples to undergo IUI before proceeding to more advanced ART. Varicocele repair before IUI significantly increased the pregnancy rate even without concomitant routine seminal parameters improvement.⁶ Varicocelectomy has also the potential to obviate the need for ART or downstage the level of ART needed to bypass male factor infertility.⁷

To our knowledge our study adds new evidence by showing that treatment for clinical varicocele in men with markedly decreased semen quality before IVF/ICSI increases the ability of the couple to conceive even in the presence of female factor infertility. The reasons for these findings may be related to the overall improvement in sperm quality. We observed significant improvement in the total number of motile sperm and a decrease in sperm defects. A higher fertilization rate was also achieved after ICSI, suggesting that the improved pregnancy rate after varicocelectomy may also have been due to functional factors that were not tested at standard semen analysis, such as seminal oxidative stress and sperm DNA integrity.

Men with increased radical oxidative stress in semen may have decreased potential for in vitro and

in vivo fertility with negative effects on embryo growth.¹⁶ Oxidative stress parameters are significantly increased in men with varicocele compared with that in sperm donors.¹⁷ High radical oxidative stress production in the reproductive tract attacks the fluidity of the sperm plasma membrane and the integrity of DNA in the sperm nucleus. Excessive DNA damage is associated with a decrease in several fertility indexes, including the fertilization, embryo cleavage, implantation and pregnancy rates.¹⁷ Infertile men with varicocele show a high level of sperm DNA damage¹⁸ but varicocele repair improves sperm DNA integrity.¹⁹

In our study the mean time from varicocelectomy to ICSI was 6.2 months. It may be argued that couples should wait longer before proceeding to ICSI to attempt natural conception. However, our rationale for varicocele repair was to achieve overall improvement in sperm quality to optimize the reproductive outcome of ICSI treatment, as previously suggested,²⁰ rather than achieve pregnancy by natural intercourse or less invasive ART modalities. Semen was improved at a postoperative followup of approximately 6 months, comprising 2 or 3 spermatogenic cycles.²¹ Couples were then free to proceed to ICSI or wait longer if desired. Nonetheless, patient motivating factors cannot be entirely controlled and many couples simply do not wait longer for natural conception after varicocelectomy. Although we cannot exclude that further improvement in semen quality or spontaneous pregnancies would be achieved if a longer interval was allowed before ICSI, our patient population included men with markedly impaired semen quality even after varicocele repair. Female factor infertility was present in a significant proportion of couples and none met the minimum criteria for IUI according to our institutional guidelines. Men who achieve a postoperative total motile sperm count of greater than 20 million are more likely to initiate pregnancy by intercourse or IUI.²² In our study the semen quality in men with treated varicocele was below this threshold.

Due to the retrospective design of our analysis the possibility of some inherent bias exists. Patients were not randomized to treatment or no treatment and the decision in regard to varicocele treatment was made by the couples. Also, the indication for ICSI may not have been based only on varicocele related infertility since about a third of the couples had significant female infertility problems that were likely to have influenced the decision making process. Moreover, couples with a good response to surgery who achieved early spontaneous pregnancy were not included in analysis, although it is likely that excluding those with a good prognosis favored the untreated group rather than benefiting the treated group. Despite these limitations demo-

graphic characteristics were homogeneous in the 2 groups, as was the seminal profile in treated and untreated men. It is our practice to advise patients with clinical varicocele who enroll in our ART program to consider varicocele treatment before assisted conception but most elect not to undergo varicocele repair. Factors influencing patient decision making were difficult to ascertain but it appeared that there were 3 main reasons to refuse treatment, including 1) the costs associated with microsurgical repair, which are not reimbursed by most health care plans in our country and would add to the already high costs of ICSI, 2) the time required to improve sperm and the uncertainty of the beneficial effect of treatment, and 3) the general belief of health care professionals and general community

that ICSI is highly successful independent of the cause of male infertility.

CONCLUSIONS

Our data suggest that varicocelectomy improves the clinical pregnancy and live birth rates by ICSI in infertile couples in whom the male partner has a clinical varicocele. Also, the chance of miscarriage may be decreased if varicocele is treated before assisted reproduction. Efforts should be made to maximize the fertility potential of the couple before assisted conception. Varicocele repair should be offered before IVF/ICSI to infertile men with clinical varicocele.

REFERENCES

- Vital and Health Statistics, series 23, No. 26. Centers for Disease Control 2002. Available at <http://www.cdc.gov>. Accessed December 22, 2009.
- Mostafa T, Anis TH, El-Nashar A et al: Varicocelectomy reduces reactive oxygen species levels and increases antioxidant activity of seminal plasma from infertile men with varicocele. *Int J Androl* 2001; **24**: 261.
- Zini A, Blumenfeld A, Libman J et al: Beneficial effect of microsurgical varicocelectomy on human sperm DNA integrity. *Hum Reprod* 2005; **20**: 1018–21.
- Esteves SC and Glina S: Recovery of spermatogenesis after microsurgical subinguinal varicocele repair in azoospermic men based on testicular histology. *Int Braz J Urol* 2005; **31**: 541.
- Marmar JL, Agarwal A, Prabakaran S et al: Reassessing the value of varicocelectomy as a treatment for male subfertility with a new meta-analysis. *Fertil Steril* 2007; **88**: 639.
- Daitch JA, Bedaiwy MA, Pasqualotto EB et al: Varicocelectomy improves intrauterine insemination success rates among men with varicoceles. *J Urol* 2001; **165**: 1510.
- Cayan S, Erdemir F, Ozbey I et al: Can varicocelectomy significantly change the way couple use assisted reproductive technologies? *J Urol* 2002; **167**: 1749.
- Marinelli C, Borges E and Antunes N: Reprodução assistida e infertilidade Masculina. II Consenso Brasileiro de Infertilidade Masculina. *Int Braz J Urol*, suppl., 2003; **29**: 42.
- Marmar JL, DeBenedictis TJ and Prais D: The management of varicoceles by microdissection of the spermatic cord at the external inguinal ring. *Fertil Steril* 1985; **43**: 583.
- World Health Organization Laboratory Manual for the Examination of Human Semen and Sperm-Cervical Mucus Interaction, 3rd ed. Cambridge, United Kingdom: Press Syndicate of University of Cambridge 1992.
- Esteves SC, Schertz JA, Verza S Jr et al: A comparison of menotropin, highly-purified menotropin and follitropin alfa in cycles of intracytoplasmic sperm injection. *Reprod Biol Endocrinol* 2009; **7**: 111.
- Esteves S, Gomes A and Verza S: Control of air pollution in assisted reproductive technology laboratory and adjacent areas improves embryo formation, cleavage and pregnancy rates and decreases abortion rate: comparison between a class 100 (ISO 5) and a class 1.000 (ISO 6) clean room for micromanipulation and embryo culture. *Fertil Steril*, suppl., 2004; **82**: 259.
- Verza S Jr and Esteves SC: Sperm defect severity rather than sperm source is associated with lower fertilization rates after intracytoplasmic sperm injection. *Int Braz J Urol* 2008; **34**: 49.
- Vecek LL: Preembryo grading. In: Atlas of the Human Oocyte and Early Conceptus. Baltimore: Williams & Wilkins 1999; vol 2, pp 62–144.
- Inci K, Hascicek M, Kara O et al: Sperm retrieval and intracytoplasmic sperm injection in men with nonobstructive azoospermia, and treated and untreated varicocele. *J Urol* 2009; **182**: 1500.
- Griveau JF and Le Lannou D: Reactive oxygen species and human spermatozoa: physiology and pathology. *Int J Androl* 1997; **20**: 61.
- Agarwal A, Prabakaran S and Allamaneni SS: Relationship between oxidative stress, varicocele and infertility: a meta-analysis. *Reprod Biomed Online* 2006; **12**: 630.
- Saleh RA, Agarwal A, Sharma RK et al: Evaluation of nuclear DNA damage in spermatozoa from infertile men with varicocele. *Fertil Steril* 2003; **80**: 1431.
- Smit M, Romijn JC, Wildhagen MF et al: Decreased sperm DNA fragmentation after surgical varicocelectomy is associated with increased pregnancy rate. *J Urol* 2010; **183**: 270.
- Yamamoto M, Hibi H, Tsuji Y et al: The effect of varicocele ligation on oocyte fertilization and pregnancy after failure of fertilization in vitro fertilization-embryo transfer. *Acta Urol Jpn* 1994; **40**: 683.
- Misell LM, Holochwost D, Boban D et al: A stable isotope-mass spectrometric method for measuring human spermatogenesis kinetics in vivo. *J Urol* 2006; **175**: 242.
- Matkov TG, Zenni M, Sandlow J et al: Preoperative semen analysis as a predictor of seminal improvement following varicocelectomy. *Fertil Steril* 2001; **75**: 63.

Varicocele as a risk factor for androgen deficiency and effect of repair

Cigdem Tanrikut^{*,†,‡}, Marc Goldstein^{*,§,¶}, James S. Rosoff^{*,§}, Richard K. Lee^{*,§}, Christian J. Nelson^{**} and John P. Mulhall^{*,**}

**Weill Cornell Medical College of Cornell University, †Massachusetts General Hospital, Boston, MA, ‡Harvard Medical School, §New York-Presbyterian Hospital, ¶Center for Biomedical Research, Population Council, and **Memorial Sloan-Kettering Cancer Center, New York, NY, USA*

Accepted for publication 28 October 2010

Study Type – Therapy (case control)
Level of Evidence 2b

OBJECTIVE

- To determine whether men with varicoceles have lower testosterone levels than those without and to ascertain if testosterone levels increase after varicocelectomy.

PATIENTS AND METHODS

- We measured preoperative testosterone levels in 325 men with palpable varicoceles and in 510 men with vasectomy reversal without varicoceles who served as a comparison group.
- The testosterone levels between groups were compared by age. Of the men with varicoceles, 200 had data on both pre- and postoperative testosterone levels, which

were compared to assess postoperative changes.

RESULTS

- Men with varicocele had significantly lower testosterone levels than the comparison group, with mean (SD) levels of 416 (156) vs 469 (192) ng/dL ($P < 0.001$). This difference persisted when analysed by age.
- The testosterone levels significantly increased after repair from 358 (126) to 454 (168) ng/dL ($P < 0.001$).
- Of the 70% of patients with postoperative improvement in testosterone levels, the mean (SD) increase in testosterone was 178 (142) ng/dL. The percentage change in testosterone levels was: 30% had no increase, 41% increased by $\leq 50\%$, 19% increased between by 51–100%, and 10% increased by $> 100\%$.
- There was no association between change in testosterone level and age,

laterality of varicocele, or varicocele grade.

CONCLUSIONS

- Men with varicoceles had significantly lower testosterone levels than the comparison group of men with vasectomy reversal.
- Microsurgical varicocele ligation resulted in a significant increase in serum testosterone levels in more than two-thirds of men.
- These findings suggest that varicocele is a significant risk factor for androgen deficiency and that repair may increase testosterone levels in men with varicocele and low testosterone levels.

KEYWORDS

varicocele, testosterone, hypogonadism, androgen deficiency

INTRODUCTION

Varicocele is an abnormal dilatation of the pampiniform plexus of veins draining the testis. Varicocele causes a well-established negative effect on spermatogenesis [1,2] and is the most common cause of male infertility. The association between varicocele and male factor infertility was first noted in the late 1800s when Bennet [3] reported an improvement in semen quality after correcting bilateral varicoceles in a patient. Thirty years later, Macomber and Sanders [4] described an infertile man with low sperm counts who became normospermic and fertile after undergoing varicocele repair. Many larger-scale studies have since shown an

improvement in semen parameters and fertility status after varicocele repair [5,6].

Multiple cross-sectional and longitudinal studies have established that, as men age, serum testosterone levels decrease [7–11]. Androgen insufficiency predisposes men to sexual dysfunction, loss of bone mineral density, sarcopenia, reduced strength and endurance, decreased energy levels, increased fatigability, and depression, as well as impaired memory, concentration and cognitive dysfunction. A growing body of evidence suggests that in addition to effects on spermatogenesis, varicocele also impairs testicular Leydig cell function with a consequential decrease in testosterone

production [12,13]; correction of the varicocele may result in improved serum testosterone levels [14]. Recent studies have also identified a higher prevalence of varicocele in men as they age [15,16]. Men with varicocele may, therefore, be at risk for premature androgen deficiency.

The present study tested two hypotheses regarding the impact of varicocele on serum testosterone:

- i) that men with varicocele have lower testosterone levels than those without varicoceles.
- ii) that surgical repair of clinically palpable varicoceles increases testosterone levels.

FIG. 1. Serum testosterone in patients with varicocele (416 ng/dL) vs comparison group (469 ng/dL), $P < 0.001$.

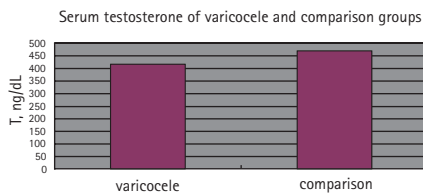


FIG. 2. Comparison of serum testosterone before (358 ng/dL) and after (454 ng/dL) varicocelectomy, $P < 0.001$.

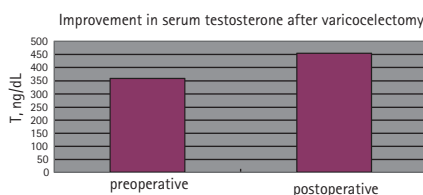


TABLE 1 Proportion of patients with unchanged or improved testosterone levels after varicocelectomy

Testosterone level response	%
No increase	30
Increase of 0–50%	41
Increase of 51–100%	19
Increase of >100%	10

PATIENTS AND METHODS

PATIENT POPULATION

This research protocol was approved by the Institutional Review Board at Weill Cornell Medical College of Cornell University. Men aged 18–70 years with clinically palpable varicoceles as determined by physical examination constituted the population group to be studied; most had primarily been referred for infertility evaluation. Surgical correction was performed via subinguinal microsurgical varicocelectomy [17]. Men presenting for vasectomy reversal surgery, with proven fertility as defined by prior conception and without varicocele on physical examination, served as the comparison group. Additional documented variables recorded included varicocele laterality, varicocele grade, and testicular volume as ascertained by physical examination using a Prader orchidometer.

Most patients with varicocele did undergo scrotal ultrasonography; however, varicocele grading was based on physical examination findings. All patients were examined by a board-certified urologist with a practice limited to andrology.

TESTOSTERONE LEVEL DETERMINATION

All men had testosterone levels measured preoperatively as assessed by a peripheral venous serum sample taken between 0800 hours and 1030 hours. If more than one preoperative serum testosterone sample had been drawn, the mean of values was used as the preoperative baseline for statistical analysis. For patients who underwent varicocelectomy, serum testosterone level was assessed at 3–12 months postoperatively for most patients. Although most men only had one postoperative blood sample drawn, if more than one serum testosterone level was drawn, the mean of values was used as the postoperative value for analysis purposes.

STATISTICAL ANALYSES

An independent measures *t*-test was used to compare testosterone levels of the comparison group to the varicocele group. An independent measures analysis of covariance (ANCOVA) was then used to control for age. In the varicocelectomy group, a repeated measure *t*-test was used to compare the preoperative serum testosterone levels to postoperative testosterone levels. Multiple regression analysis was used to identify potential predictors of the change in testosterone levels before and after surgery. The variables tested as predictors were age, mean testicular volume, testicular volume group (<16 mL on either side vs other), or varicocele grade (grade 3 on either side vs other).

RESULTS

PATIENT POPULATION

In all, 325 men with varicocele were compared with 510 men in the comparison group. As a group, the patients with varicoceles were significantly younger than the comparison group, with a mean (SD) age of 35 (8) years vs 43 (8) years ($P < 0.001$). In the patients with varicocele, 225 (70%) had bilateral varicoceles, 92 (28%) had unilateral, while eight (2%) had no designation. For left

varicocele grade, 20 (7%) had a grade I, 73 (25%) had a grade II, and 203 (68%) had a grade III. When focusing on right varicocele grade, 69 (29%) had a grade I, 110 (46%) had a grade II, 42 (17%) had a grade III.

COMPARISON OF TESTOSTERONE LEVELS BETWEEN GROUPS

Men with varicocele had significantly lower mean (SD) serum testosterone levels than the comparison group, at 416 (156) ng/dL vs 469 (192) ng/dL ($P < 0.001$; Fig. 1). As it is well established that age is associated with testosterone levels, age was used as a covariate in an ANCOVA analysis. When including age as a covariate, the significant difference in testosterone levels remained between the groups ($F = 29.01, P < 0.001$). When controlling for age, the testosterone level of the varicocele group remained significantly lower (testosterone level 402 ng/dL) compared with the comparison group (testosterone level 478 ng/dL).

CHANGES IN TESTOSTERONE LEVELS AFTER VARICOCELECTOMY

Of the patients who had undergone varicocelectomy, 200 had documented postoperative serum testosterone values. The mean (SD) age of this group was 36 (8) years. After microsurgical varicocelectomy, patients' postoperative serum testosterone levels were significantly higher than their preoperative levels, at a mean (SD) of 454 (168) ng/dL vs 358 (126) ng/dL ($P < 0.001$; Fig. 2). Most patients exhibited an increase in serum testosterone levels postoperatively (Table 1). For patients with postoperative testosterone level improvement (142 men), the mean (SD) increase in testosterone level was 178 (142) ng/dL. Of those patients with testosterone levels of <300 ng/dL preoperatively (58 men), 79% had their testosterone levels increase to >300 ng/dL postoperatively. Conversely, of those patients with testosterone levels of >300 ng/dL preoperatively (142 men), only 12% had a testosterone level decline to <300 ng/dL. Multiple regression analysis was used to identify potential predictors of the change in testosterone levels before and after surgery. Variables tested as predictors were age, mean testicular volume, testicular volume group (<16 mL on either side vs other), or varicocele grade (grade 3 on either side vs other). There were no predictors of change in testosterone levels.

The preoperative endocrine data accumulated for the patients with varicocele also included serum levels of FSH, luteinizing hormone (LH), and oestradiol. The mean values were within the normal range for each hormone. Too few patients had postoperative levels drawn for a meaningful preoperative/postoperative comparison.

DISCUSSION

The negative impact of varicocele on spermatogenesis has long been recognized. For clinically significant varicoceles, varicocele ligation is performed with the goal of improving semen parameters in the setting of subfertility. The association between clinically significant varicocele and impaired testosterone production is less well-established. Furthermore, the utility of varicocelectomy for optimizing Leydig cell function and testosterone production has not yet been studied.

Varicoceles are diagnosed in up to 15% of the general population [18], in about one-third of men who present for evaluation of primary infertility [5,6] and in as many as 80% of patients with secondary infertility [2,19]. The vast majority of varicoceles are left-sided or bilateral with left generally larger than right. For impact on semen parameters, varicoceles are associated with lower sperm concentration, reduced motility and/or abnormal morphology on semen analysis [1,3,20]. Larger varicoceles cause more severe impairment of testis function [19]. These and other studies suggest that varicocele induces progressive, duration-dependent damage to the testes [19,21]. Semen parameters and fertility status improve after varicocele repair [4–6,22]

Several hypotheses have been suggested to explain how varicocele has a deleterious effect on testis function. The most widely accepted of these theories relates to alterations in the testicular thermal environment. Under normal scrotal conditions, a counter-current heat-exchange mechanism between the outflow of the pampiniform plexus and testicular arterial inflow supports the cooler temperature required for optimal sperm production [23]. Multiple studies indicate disruption of this cooling mechanism in patients with varicocele, leading to elevated scrotal and testicular temperatures [24,25]. Further, a

reduction in testicular temperature has been shown to occur after varicocele repair. The heat impact on spermatogenic function may be independent of local effects on testicular testosterone production [26].

For varicocele repair, subinguinal microsurgical varicocelectomy is the repair technique with the lowest reported rates of failure and morbidity [17]. A small incision is made overlying the external inguinal ring and the spermatic cord is mobilized and spermatic veins are ligated with preservation of the vasal complex, testicular arteries and lymphatics.

In addition to the negative effects on semen parameters, varicocele has also been associated with diminished serum testosterone levels in infertile men; correction of the varicocele may result in improved serum testosterone levels [14]. Additional reports indicate that varicocele-related impairment of testicular Leydig cell function, as evidenced by decreased serum testosterone levels, also occurs in men without infertility [12,13]. It has been well-established that serum testosterone levels decrease as men age [7–11,26]. Recent studies have also identified a higher prevalence of varicocele in men with increasing age [15,16]. Given consideration of these separate findings, taken together it is reasonable to propose that men with varicocele may be at risk for premature androgen deficiency and that varicocele repair may reduce this risk.

The mechanism by which varicocele impairs testosterone production has not yet been clearly identified. Studies have shown abnormalities in the hypothalamic-pituitary-testis axis of infertile men with varicoceles [28,29]. An *in vitro* study of testicular tissue obtained from oligospermic men with varicoceles showed suppressed testosterone production [30]. Similar to the hypothesis regarding varicocele and its pathophysiological impact on spermatogenesis, thermal alterations may also negatively affect testosterone synthesis [14,27]. Varicocele has been implicated in altered function of 17 α -hydroxyprogesteronealdolase, which converts 17-hydroxyprogesterone to testosterone. Heat effects related to varicocele could have a negative effect on the enzyme's action, thus resulting in decreased testosterone production [31]. The documented temperature decrease reported after correction of

varicocele may improve the Leydig cell environment for enzyme activity, thus resulting in postoperative improvement in serum testosterone levels as in the present study.

An interesting rat model of varicocele and varicocelectomy recently implicated varicocele as causing deterioration in intratesticular testosterone production, and showed that artery-preserving varicocele repair resulted in correction of the intratesticular testosterone to normal levels [32]. Further experimental and clinical studies are appropriate to substantiate or refute the suggestion that thermal effects are associated with decreases in testosterone production in men.

The present study confirms that men with varicoceles have lower testosterone levels compared with a comparison group without varicocele across age categories. Although there were statistically significant differences between the ages of the varicocele group and the comparison group, in each case the varicocele group had a lower mean age than that of those in the comparison group; this indicates that the 'true' difference in testosterone levels is, perhaps, even *more* significant than that identified in the present study. Based on the present findings, it appears that men with varicoceles have an accelerated deterioration in testosterone levels as compared with the normal age-related decline.

The present findings also indicate microsurgical varicocelectomy as a means to improve serum testosterone levels. The nearly 100 ng/dL increase in serum testosterone levels after surgery, from 358 ng/dL preoperatively to 454 ng/dL postoperatively, in the varicocelectomy population as a whole corroborates similar results reported in a previous study in a smaller cohort of patients [14]. In addition, the mean improvement in testosterone of >150 ng/dL in those patients who did exhibit postoperative testosterone increases would be expected to be clinically significant.

Sample sizes for the two groups evaluated were large, with convincing statistical findings related to testosterone level differences between the two groups and the postoperative changes in testosterone levels within the varicocelectomy group. However, given that this was a retrospective study,

selection bias may exist. Most, but not all, patients with varicocele had been referred for fertility evaluation, so the referral population was not entirely homogeneous. Further, longer scheduled follow-up to assess durability of improvements in testosterone levels would help ascertain the long-term benefits of varicocele repair on men's health.

For the comparison group, men seeking vasectomy reversal were used. However, men seeking vasectomy reversal may represent a population of men with intrinsically higher-than-average serum testosterone levels for age. A better comparison would be recruitment of randomly selected men without fertility issues, not seeking vasectomy reversal, to serve as a true control group. In addition, it would be interesting to include a third group comprised of men with varicocele and without infertility to assess how their serum testosterone levels compare with these two groups.

These data strongly suggest that varicocele is a significant risk factor for androgen deficiency and that microsurgical repair of clinically palpable varicoceles significantly increases testosterone levels in men with varicocele and low serum testosterone levels. At the very least, repair is likely to restore men to the normal slope of age-related decline in testosterone.

In conclusion, varicocele is a risk factor for androgen deficiency. Microsurgical repair significantly increases testosterone levels. The identification of varicocele as a treatable cause of androgen deficiency has broad implications for maintenance of general male health and well-being.

ACKNOWLEDGMENTS

The authors thank Joshua Bloomberg, Judy Choi, and Sam Finkelberg, RN for data accumulation and data entry. This study was supported by the Frederick J. and Theresa Dow Wallace Fund of the New York Community Trust.

CONFLICT OF INTEREST

None declared.

REFERENCES

- World Health Organization. The influence of varicocele on parameters of fertility in a large group of men presenting in infertility clinics. *Fertil Steril* 1992; **57**: 1289–93
- Gorelick JI, Goldstein M. Loss of fertility in men with varicocele. *Fertil Steril* 1993; **59**: 613–16
- Bennet WH. Varicocele, particularly with reference to its radical cure. *Lancet* 1889; **1**: 261–2
- Macomber D, Sanders MB. The spermatozoa count: its value in the diagnosis, prognosis and treatment of sterility. *N Engl J Med* 1929; **200**: 981–4
- Dubin L, Amelar RD. Varicocelectomy: 986 cases in a twelve-year study. *Urology* 1977; **10**: 446–9
- Greenberg SH, Lipshultz LI, Wein AJ. Experience with 425 subfertile male patients. *J Urol* 1978; **119**: 507–10
- Gray A, Feldman HA, McKinlay JB, Longcope C. Age, disease, and changing sex hormone levels in middle-aged men: results of the Massachusetts Male Aging Study. *J Clin Endocrinol Metab* 1991; **73**: 1016–25
- Orwoll E, Lambert LC, Marshall LM *et al*. Testosterone and estradiol among older men. *J Clin Endocrinol Metab* 2006; **91**: 1336–44
- Harman SM, Metter EJ, Tobin JD, Pearson J, Blackman MR. Longitudinal effects of aging on serum total and free testosterone levels in healthy men. Baltimore Longitudinal Study of Aging. *J Clin Endocrinol Metab* 2001; **86**: 724–31
- Travison TG, Araujo AB, Kupelian V, O'Donnell AB, McKinlay JB. The relative contributions of aging, health, and lifestyle factors to serum testosterone decline in men. *J Clin Endocrinol Metab* 2007; **92**: 549–55
- Wu FC, Tajar A, Pye SR *et al*. Hypothalamic-pituitary-testicular axis disruptions in older men are differentially linked to age and modifiable risk factors. *J Clin Endocrinol Metab* 2008; **93**: 2737–45
- Comhaire F, Vermeulen A. Plasma testosterone in patients with varicocele and sexual inadequacy. *J Clin Endocrinol Metab* 1975; **40**: 824–9
- Pirke KM, Vogt HJ, Sintermann R, Spyra B. Testosterone in peripheral plasma, spermatic vein and in testicular tissue under basal conditions and after HCG-stimulation in patients with varicocele. *Andrologia* 1983; **15**: 637–41
- Su LM, Goldstein M, Schlegel PN. The effect of varicocelectomy on serum testosterone levels in infertile men with varicoceles. *J Urol* 1995; **154**: 1752–5
- Canales BK, Zapzalka DM, Ercole CJ *et al*. Prevalence and effect of varicoceles in an elderly population. *Urology* 2005; **66**: 627–31
- Levinger U, Gornish M, Gat Y, Bachar GN. Is varicocele prevalence increasing with age? *Andrologia* 2007; **39**: 77–80
- Goldstein M, Tanrikut C. Microsurgical management of male infertility. *Nat Clin Pract Urol* 2006; **3**: 381–91
- Meacham RB, Townsend RR, Rademacher D, Drose JA. The incidence of varicoceles in the general population when evaluated by physical examination, gray scale sonography and color Doppler sonography. *J Urol* 1994; **151**: 1535–38
- Steckel J, Dicker AI, Goldstein M. Relationship between varicocele size and response to varicocelectomy. *J Urol* 1993; **149**: 769–71
- Nagao RR, Plymate SR, Berger RE, Perin EB, Paulsen CA. Comparison of gonadal function between fertile and infertile men with varicoceles. *Fertil Steril* 1986; **46**: 930–3
- Witt MA, Lipshultz LI. Varicocele: a progressive or static lesion? *Urology* 1993; **42**: 541–3
- Marmar JL, Agarwal A, Prabakaran S *et al*. Reassessing the value of varicocelectomy as a treatment for male subfertility with a new meta-analysis. *Fertil Steril* 2007; **88**: 639–48
- Zorgniotti AW. Testis temperature, infertility, and the varicocele paradox. *Urology* 1980; **16**: 7–10
- Tessler AN, Kahn HP. Varicocele and testicular temperature. *Fertil Steril* 1966; **17**: 201–3
- Lewis RW, Harrison RM. Contact scrotal thermography: application to problems of fertility. *J Urol* 1979; **122**: 40–2
- Yin Y, Stahl BC, DeWolf WC, Morgentaler A. Heat-induced testicular apoptosis occurs independently of hormonal depletion. *Apoptosis* 1998; **3**: 281–7
- Raboch J, Stárka L. Hormonal testicular activity in men with a varicocele. *Fertil Steril* 1971; **22**: 152–5
- Swerdlow RS, Walsh PC. Pituitary and gonadal hormones in patients with varicocele. *Fertil Steril* 1975; **26**: 1006–12
- Weiss DB, Rodriguez-Rigua LJ, Smith KD, Steinberger E. Leydig cell function in

oligospermic men with varicocele. *J Urol* 1978; **120**: 427–30

- 30 **Wright EJ, Young GP, Goldstein M.** Reduction in testicular temperature after varicocelectomy in infertile men. *Urology* 1997; **50**: 257–9
- 31 **Ando S, Giacchetto C, Colpi G.** Plasma levels of 17-OH-progesterone and

testosterone in patients with varicoceles. *Acta Endocrinol (Copenh)* 1983; **102**: 463–9

- 32 **Zheng YQ, Zhang XB, Zhou JQ.** The effects of artery-ligating and artery-preserving varicocelectomy on the ipsilateral testes in rats. *Urology* 2008; **72**: 1179–84

Correspondence: Cigdem Tanrikut, Massachusetts General Hospital, 55 Fruit Street, YAW 10A, Boston, MA 02114, USA. e-mail: ctanrikut@partners.org

Abbreviation: ANCOVA, analysis of covariance.

Loss of fertility in men with varicocele*

Jeffrey I. Gorelick, M.D.†
Marc Goldstein, M.D.†‡§

The New York Hospital-Cornell Medical Center, and The Population Council, New York, New York

Objective: To test the hypothesis that men with varicocele who have already fathered children are immune to the detrimental effect of varicocele on their fertility and will continue to be fertile. If this were the case, one would expect a very low incidence of varicocele in currently infertile men who were able to father a child in the past (secondary infertility) compared with men who have never been fertile (primary infertility).

Design: Survey of men with male factor infertility.

Setting: Tertiary care university medical center.

Patients: One thousand ninety-nine infertile men of whom 98 (9%) met our criteria for secondary infertility. Men with prior vasectomy and men whose partners were over age 40 were excluded.

Main Outcome Measure: Difference in the incidence of varicocele in men with secondary infertility versus primary infertility.

Results: A varicocele was palpable in 35% (352/1,001) of men with primary infertility and 81% (79/98) of men with secondary infertility. This difference in the incidence of varicocele was highly significant. Men with secondary infertility and varicocele were slightly older (37.9 versus 33.5 years), had a lower mean sperm concentration (30.2 versus $46.1 \times 10^6/\text{mL}$), more abnormally shaped sperm (72% versus 40%), and higher mean serum follicle-stimulating hormone levels (17.6 versus 7.9 mIU/mL) compared with men with primary infertility and varicocele.

Conclusions: The incidence of varicocele is much higher in male factor secondary infertility compared with primary infertility. These findings suggest that varicocele causes a progressive decline in fertility and that prior fertility in men with varicocele does not predict resistance to varicocele induced impairment of spermatogenesis. Men with a varicocele may benefit from early evaluation and prophylactic varicocelectomy to prevent future infertility. *Fertil Steril* 1993;59:613-6

Key Words: Varicocele, infertility, secondary infertility, loss of fertility

The incidence of palpable varicocele is higher among infertile men (21% to 41%) compared with the general population (4.4% to 22.6%) (1). Studies in animals (2-4) and humans (5, 6) suggest that varicocele causes progressive duration dependent

testicular damage. Although varicocele is associated with infertility, many men with varicoceles father children. It is possible that those men with varicoceles who are of proven fertility are resistant to the detrimental effects of varicocele on spermatogenesis. If this were true, one would expect a lower incidence of varicocele in men who are currently infertile but who were able to father a child in the past (secondary infertility) compared with men who have never been fertile (primary infertility). If, however, the detrimental effect of varicocele on spermatogenesis is a progressive phenomenon and it is simply a matter of time before testicular injury becomes clinically evident, one would then expect a higher incidence of varicocele in men with secondary infertility compared with men with primary infertility.

Received June 24, 1992; revised and accepted October 27, 1992.

* Presented in part at the 45th Annual Meeting of The American Fertility Society, San Francisco, California, November 13 to 16, 1989.

† Division of Male Reproduction and Microsurgery, Department of Urology, The New York Hospital-Cornell Medical Center.

‡ Center for Biomedical Research, The Population Council.

§ Reprint requests: Marc Goldstein, M.D., Department of Urology, The New York Hospital-Cornell Medical Center, 525 East 68th Street, New York, New York 10021.

In the present study, we determined the incidence of varicocele in men presenting with primary versus secondary infertility. We then compared the semen analyses as well as the serum testosterone (T) and follicle-stimulating hormone (FSH) levels in men with primary infertility and varicocele versus men with secondary infertility and varicocele.

MATERIALS AND METHODS

Patients

The records of 1,300 consecutive men presenting with suspected male factor infertility were reviewed. Male factor infertility was defined as: [1] failure to achieve pregnancy with current partner after unprotected coitus for at least 1 year and [2] present female partner having been previously pregnant and/or having undergone complete gynecological infertility examination to rule out any identifiable female factors. Men whose partners were over 40 years of age were excluded. Men presenting for reversal of vasectomy were excluded from this study.

A complete medical and reproductive history was obtained from all men. This included age, age of partner, duration of infertility, previous pregnancies and pregnancy outcomes, and history of any prior systemic or genitourinary disorders. All patients underwent a complete physical examination by the same physician in a warm room. Varicoceles were graded as follows: *small*: distinct dilation of the internal spermatic veins palpable during a Valsalva maneuver in the upright position; *moderate*: palpable in the upright position without the aid of a Valsalva maneuver; *large*: both palpable and visible through the scrotal skin, without the aid of a Valsalva maneuver in the upright position. The diagnosis of varicocele was independently confirmed by another examiner. Men with only subclinical varicoceles diagnosed by Doppler, sonography, or venography were excluded from the study.

Semen was obtained by masturbation after between 2 and 5 days of abstinence and examined within 30 minutes of ejaculation. Semen volume, sperm concentration, percent and progression of motility, and morphology were recorded as per World Health Organization (WHO) recommendations (7). The mean number of ejaculates collected was 2.3 per patient (range, 1 to 4). Serum T and FSH levels were determined by standard radioimmunoassay.

Statistical analysis of differences between groups was performed using Student's *t*-test. To ensure va-

lidity of these *t*-tests, data were evaluated for normality of distribution via normal probability plots and for equality of group variances via the variance ratio *F*-test. Abnormal sperm motility and morphology comparisons were carried out by means of the χ^2 test.

RESULTS

Review of 1,300 consecutive infertility visit records identified 1,099 men who met our criteria for male factor infertility. One thousand one (91%) of these men presented with primary (1°) infertility and 98 (9%) men met our criteria for secondary (2°) infertility defined as previously demonstrated paternity on at least one occasion with either present or former partners. A varicocele was palpable in 35% (352/1,001) of men with 1° infertility and 81% (79/98) of men with 2° infertility. This difference in incidence of varicocele was significant ($P < 0.001$).

The mean age of men with 1° infertility and varicocele was 33.5 years (range, 22 to 49 years), and the mean age of their female partners was 31.7 years (range, 19 to 40 years). The mean age of men with 2° infertility and varicocele was 37.9 years (range, 25 to 56), and the mean age of their female partners was 33.8 years (range, 18 to 40 years). The mean duration of unprotected intercourse for these couples was 28 months in the 1° infertility and varicocele group and 21 months in the 2° infertility and varicocele group. The 79 men with 2° infertility and varicocele had been responsible for a total of 134 known pregnancies for a mean of 1.7 paternities per patient (range, 1 to 5). Fifty-one (65%) had impregnated their present partner, and 15 of these men had achieved pregnancies with former partners as well. The remaining 28 (35%) men had achieved pregnancies with prior partners only. The mean duration since last known paternity was 8.8 years (range, 1 to 24). Two thirds of the partners of men with 2° infertility and varicocele had been pregnant in the past and also had a recent gynecological exam revealing no identifiable female infertility factor. The remainder fulfilled at least one of these criteria.

Varicocele size and laterality data are depicted in Table 1. The differences between men with 1° versus 2° infertility were not significant.

Semen analysis data are presented in Table 2. Two thirds of men with 2° infertility and varicocele had sperm concentrations under 40×10^6 /mL and nearly 40% had counts $< 20 \times 10^6$ sperm/mL. The mean sperm concentration for these men was 30.2 million sperm/mL compared with 46.1 for men with 1° in-

Table 1 Varicocele: Location and Size

	1° infertility	2° infertility
Location		
Left	195 (65)*	46 (58)
Right	10 (3)	3 (4)
Bilateral	147 (42)	30 (38)
Total	352	79
Size		
Small	188 (43)	39 (36)
Moderate	179 (32)	47 (43)
Large	129 (25)	23 (21)
Total	499	109

* Values in parentheses are percents.

fertility and varicocele ($P < 0.01$). Subnormal sperm motility (i.e., <40% motile sperm) was noted in 43% of men with 2° infertility and varicocele compared with 40% of men with 1° infertility and varicocele ($P =$ not significant). Abnormal sperm morphology (i.e., >60% abnormal forms) was observed in 72% of men with 2° infertility and varicocele compared with only 40% of men with 1° infertility and varicocele.

The mean values for serum T and FSH were within normal limits for both groups (Table 2). The mean T level was lower for men with 2° infertility and varicocele (507 versus 585) ($P < 0.05$). These men also exhibited a significantly higher mean FSH level (17.6 mIU/mL) than men with 1° infertility and varicocele (7.9 mIU/mL), ($P < 0.001$).

DISCUSSION

Varicocele is a common finding on the physical examination of young men. Although the incidence of varicocele in infertile men is increased compared with the incidence in the general population, many men with varicocele father children. We hypothesized that men with varicocele who are of proven fertility are resistant to varicocele-induced impair-

ment of testicular function. If this hypothesis were correct, one would expect that those men with varicocele who already fathered children have demonstrated their immunity to the detrimental effect of varicocele on their fertility and will continue to be fertile. If this were true, the incidence of varicocele in men with secondary infertility should be very low. Our data, however, refute this hypothesis.

We found that varicocele was the most common abnormality associated with nonvasectomy related male factor secondary infertility. It is present in a significantly higher percentage of men with secondary (81%) as compared with primary (35%) infertility. In addition, although of prior proven fertility, men with 2° infertility and varicocele had a significantly lower mean sperm concentration and poorer sperm morphology than did men with varicocele and primary infertility. The significantly higher mean serum FSH level in men with 2° infertility and varicocele suggests a greater degree of seminiferous tubular injury. Although the men with 2° infertility were slightly older (37.9 years) than men with primary infertility (33.5 years), age alone would not account for their loss of fertility (8). The difference in the age of the female partners (31.7 for primary versus 33.8 for secondary) is too small to explain a significant decline in fertility. It is likely that the detrimental effect of varicocele on the testicular function of these men since last known paternity (mean, 8.8 years) is responsible for the observed loss of fertility in these men. An alternative explanation for the higher prevalence of varicoceles in the secondary infertile population is that other causes of male factor infertility may decrease rather than varicoceles increase. This seems unlikely, however, because the cumulative effects of other common infertility etiologies such as infection with resultant obstruction, exposure to the gonadotoxic effects of drug or alcohol abuse, or the effect of chronic diseases such as diabetes, would be expected to increase rather than decrease over time.

Table 2 Semen Analysis and Endocrine Data of Men With Varicocele

	1° infertility (n = 352)	2° infertility (n = 79)	Probability
Sperm concentration ($\times 10^6$ /mL)	46.1 \pm 1.21 (0 to 96.0)*	30.2 \pm 1.46 (0 to 107)	<0.01
Abnormal motility (<40% motile)	141 [40]†	34 [43]	NS†
Abnormal morphology (<40% abnormal forms)	140 [40]	57 [72]	<0.001
Serum T (ng/dL) (normal = 300 to 1,000)	585 \pm 0.88 (88 to 1,808)	507 \pm 0.51 (70 to 1,288)	<0.05
Serum FSH (mIU/mL) (normal = 4.2 to 19)	7.9 \pm 0.03 (2 to 75)	17.6 \pm 0.54 (2 to 87)	<0.001

* Values are means \pm SEM with ranges in parentheses.

† NS, not significant.

† Values in brackets are percents.

Our explanation of the increased incidence of varicocele in secondary infertility is supported by studies in animals suggesting that varicocele produces a progressive, duration dependent deterioration of seminiferous tubular function. Harrison et al. (4) surgically created varicoceles in monkeys and noted a progressive decline in sperm concentration, percent normal morphology, and motility over time. Saypol and colleagues (2) showed histologic changes to be worse at 3 months compared with 1 month after surgical creation of varicoceles in rats and dogs. Nagler et al. (3) reported identical findings in rats.

Several studies in humans support the concept of duration-dependent testicular injury with varicocele. Russell (5) observed that of 48 men with varicoceles, 82% of those older than 30 years had sperm concentrations $< 20 \times 10^6$ compared with 30% of those younger than 30 years old. Lipshultz and Corriere (6) compared subfertile patients with varicoceles, fertile patients with varicoceles, and normal controls. Although the fertile patients with varicoceles had normal semen analyses, they had a significant diminution in testicular volume compared with controls, as did the subfertile varicocele group. The subfertile group was significantly older than the fertile men with varicoceles. Nagao and colleagues (9) studied fertile men with varicoceles ($n = 42$), subfertile men with varicoceles ($n = 24$), and a control group ($n = 55$). The fertile men with varicoceles had significantly higher sperm concentrations than their subfertile counterparts, but both groups had elevated baseline luteinizing hormone (LH) values and had significantly higher LH responses to administration of LH-releasing hormone than the control group. Their study identified a subgroup of men with varicoceles who, despite proven fertility, exhibited evidence of subclinical testicular dysfunction. This dysfunction may precede gross deterioration in semen quality. Cheval and Purcell (10) followed a cohort of men with normal semen parameters and varicoceles over time and clearly demonstrated a significant decline in sperm count and motility. A WHO study of 9,034 men found that the incidence of varicocele in men with abnormal semen was more than twice that of men with normal semen and that varicocele was accompanied by decreased testicular volume (11).

Our current observations as well as prior studies in animals and humans suggest that varicocele causes a progressive decline in fertility and that prior fertility in men with varicocele does not assure future fertility. In adolescents and young men with varicoceles, age at the time of marriage and attempt at

conception is unpredictable. Those who marry early are likely to be more successful in impregnating their partners than those who delay. Encouraging early marriage and attempts at conception for young men with varicocele is one approach to this problem. Alternatively, young men with varicocele may benefit from early evaluation to detect testicular atrophy or abnormal semen analysis. Varicoceles may now be repaired with minimal risk of morbidity (12). Prophylactic varicocele repair may prevent future infertility in men with varicocele (13).

Acknowledgments. We are indebted to Claire Gnecco, Ph.D., of the Division of Biostatistics, Memorial Sloan-Kettering Cancer Center, New York, New York, for statistical consultation and E. Dartcott Vaughan, Jr., M.D., James Buchanan Brady Foundation, Division of Urology, The New York Hospital-Cornell Medical Center, New York, New York, and C. Wayne Bardin, M.D., The Population Council, New York, New York, for their critical review of the manuscript. We thank Ms. Jean Schweis and staff at The Population Council for help in the preparation of the manuscript.

REFERENCES

1. Saypol DC. Varicocele. *J Androl* 1981;2:61-71.
2. Saypol DC, Howards SS, Turner TT, Miller ED. Influence of surgically induced varicocele on testicular blood flow, temperature, and histology in adult rats and dogs. *J Clin Invest* 1981;68:39-45.
3. Nagler HM, Li X-Z, Lizza EF, Deitch A, White RD. Varicocele: temporal considerations. *J Urol* 1985;134:411-3.
4. Harrison RM, Lewis RW, Roberts JA. Pathophysiology of varicocele in nonhuman primates: long-term seminal and testicular changes. *Fertil Steril* 1986;46:500-10.
5. Russell JK. Varicocele, age, and fertility. *Lancet* 1957;2:222.
6. Lipshultz JL, Corriere JN. Progressive testicular atrophy in the varicocele patient. *J Urol* 1977;117:175-6.
7. World Health Organization. WHO laboratory manual for the examination of human semen and semen-cervical mucus interaction. 2nd edition. Cambridge: The Press Syndicate of the University of Cambridge, 1987:3-15.
8. Nieschlag E, Lammers U, Freischerm CW. Reproductive functions in young fathers and grandfathers. *J Clin Endocrinol Metab* 1982;55:676-81.
9. Nagao RR, Plymate SR, Berger RE, Perin EB, Paulsen AC. *Comparison of gonadal function between fertile and infertile men with varicoceles.* *Fertil Steril* 1986;46:930-3.
10. Cheval MJ, Purcell MH. Deterioration of semen parameters over time in men with untreated varicocele: evidence of progressive testicular damage. *Fertil Steril* 1992;57:174-7.
11. World Health Organization. The influence of varicocele on parameters of fertility in a large group of men presenting to infertility clinics. *Fertil Steril* 1992;57:1289-93.
12. Goldstein M, Gilbert BR, Dicker AP, Dwosh J, Gnecco C. Microsurgical inguinal varicocelectomy with delivery of the testis: an artery and lymphatic sparing technique. *J Urol* 1992;148:1808-11.
13. Kass EJ, Belman AB. Reversal of testicular growth failure by varicocele ligation. *J Urol* 1987;137:475-6.

Microsurgical management of male infertility

Marc Goldstein* and Cigdem Tanrikut

SUMMARY

The introduction of microsurgical techniques has revolutionized the treatment of male infertility. As a result of technical advances and innovation over the past 10–15 years, previously infertile couples are now able to conceive naturally or to parent their own biological children with the aid of assisted reproductive technologies. This article reviews the indications, techniques, and outcomes of the various microsurgical procedures currently used to optimize male fertility. The most up-to-date methods of microsurgical vasal and epididymal reconstruction, sperm retrieval, and varicocele repair are discussed.

KEYWORDS male infertility, microsurgery, varicocele, vasoepididymostomy, vasovasostomy

REVIEW CRITERIA

Information presented in this review is based on the authors' extensive collection of research papers, textbooks, and Marc Goldstein's vast personal experience in the field of male infertility.

INTRODUCTION

According to the Centers for Disease Control and Prevention 2003 Assisted Reproductive Technology (ART) Report, male factors play a significant role in 30–40% of couples dealing with infertility.¹ The more common causes of infertility in men include obstruction of the reproductive tract, which can be congenital, acquired or iatrogenic, and impairment of sperm production associated with karyotypic or Y-chromosomal abnormalities, testicular pathology or the presence of varicocele. Most causes of male infertility are treatable, and many treatments restore the ability to conceive naturally.

The dramatic recent improvements in the management of male infertility are largely attributable to improved microsurgical techniques for the repair of obstruction, microsurgical varicocelectomy for enhancement of spermatogenesis, new options for sperm retrieval, and refined microsurgical intracytoplasmic sperm injection (ICSI). These factors have made male infertility one of the fastest growing subspecialties of urology.^{2–11}

VASAL AND EPIDIDYMAL OBSTRUCTION

The most common causes of vasal and epididymal obstructions are vasectomy and iatrogenic vasal injury (7% of cases) from previous scrotal/inguinal surgeries, particularly those performed in childhood.^{12,13} Microsurgical reconstruction remains the safest and most cost-effective treatment option for these patients,^{14–16} and also allows natural conception, which is preferred by couples.

The lumina of the vas deferens and epididymal tubule are only about 0.3 mm and 0.2 mm in diameter, respectively, and, therefore, a precise microsurgical technique is the most important factor in the success of reconstruction (as defined by return of sperm to the ejaculate). With recent improvements in microsurgical techniques, the success rate for vasovasostomy is between 70% and 99%,^{2,3,17,18} and success rates between 40% and 90% have

M Goldstein is a Professor of Reproductive Medicine and a Professor of Urology, and C Tanrikut is a Fellow in Male Reproductive Medicine and Microsurgery, at Weill Medical College of Cornell University, New York, NY, USA.

Correspondence

*Weill Medical College of Cornell University, Cornell Institute for Reproductive Medicine, PO Box 580, 525 East 68th Street, New York, NY 10021, USA
mgoldst@med.cornell.edu

Received 27 September 2005 Accepted 18 May 2006

www.nature.com/clinicalpractice
doi:10.1038/ncpuro0524

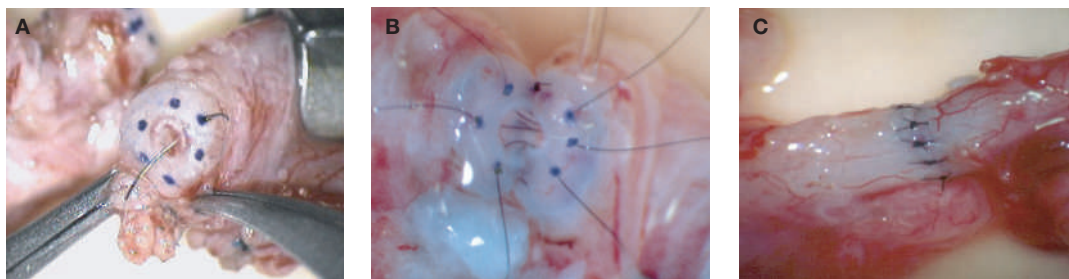


Figure 1 Microsurgical vasovasostomy with multilayer microdot method ($\times 25$). **(A)** Placement of 10-0 nylon suture inside the vasal lumen and through the microdot target. **(B)** The first three (of six) sutures of the anastomosis have been placed and tied down. The final three sutures have been placed and are ready to be tied. **(C)** Completed anastomosis. Reproduced with permission from reference 23 © (2002) Elsevier Inc.

been reported for microsurgical vasoepididymostomy.^{2,6,19,20} Many patient-related factors, such as time interval from vasectomy, sperm granuloma at the site of anastomosis,²¹ antisperm antibodies²² and gross appearance of the vasal fluid,²³ can influence the outcome of the reconstruction. The age of the female partner should also be taken into account.²⁴ In addition, the surgeon's skill, reconstructive technique and experience all have a significant impact on surgical outcome.

MICROSURGICAL VASECTOMY REVERSAL

Vasectomy is the most common urologic operation in North America, where between 500,000 and 1 million men undergo the procedure each year. Before undergoing vasectomy, the patient should receive counseling regarding the permanency of the procedure and be offered the option of sperm banking. Despite preoperative counseling, surveys suggest that 2–6% of vasectomized men will ultimately seek vasectomy reversal because of unforeseen changes in lifestyle.²⁵

Vasovasostomy

The microdot technique was developed at Cornell University as a means of improving the vasovasostomy procedure. It ensures precise suture placement by the exact mapping of each planned suture. When sperm are found in the fluid emanating from the testicular end of the vas, the patency rate of this technique for return of sperm to the ejaculate is 99.5%, and the 1-year cumulative pregnancy rate for partners of patients undergoing this procedure is 70%.³ The microdot method separates the planning of suture position from the physical act of suture placement. Much as an architect prepares

blueprints before the builder constructs the house, the perioperative planning of suture placement is critical to a successful surgical outcome. This painstaking planning allows the surgeon to focus on one task at the time of suture placement, 'hitting the bulls eye'. In addition, the discrepancy in diameter between the proximal (obstructed) vasal lumen and the distal (nonobstructed) vasal lumen is typically 2:1 to 3:1, sometimes more; careful, even spacing of the sutures minimizes luminal discrepancy and limits 'dogears' and leaks, thus decreasing the risk of postoperative stricture, granuloma formation, and reconstructive failure. The microdot method results in substantially improved accuracy of suture placement and minimizes the discrepancy between luminal diameters of the proximal and distal vasal ends, allowing for a watertight anastomosis.

A microtip skin-marking pen is used to map out planned needle exit points. Exactly six monofilament 10-0 double-arm nylon mucosal sutures (first layer) are used for every anastomosis, because they are easy to map out and always result in a leak-proof closure, even when the lumen diameters are markedly discrepant. After completion of the mucosal layer, six 9-0 deep muscularis sutures are placed exactly in between each mucosal suture, just above, but not penetrating, the mucosa (second layer). Six additional 9-0 nylon interrupted sutures are then placed between each muscular suture (third layer). These sutures only involve the adventitial layer that covers the underlying mucosal suture. The anastomosis is finished by approximating the vasal sheath with six interrupted sutures of 7-0 PDS, completely covering the anastomosis and relieving it of all tension (fourth layer). All anastomoses consist of four layers of

Table 1 Surgical recommendations based on gross appearance of vasal fluid and microscopic findings.

Appearance of vasal fluid	Most common findings on microscopic examination	Surgical procedure recommended
Copious, crystal clear, watery	No sperm	Vasovasostomy
Copious, cloudy thin, water soluble	Sperm with tails	Vasovasostomy
Copious, creamy yellow, water insoluble	Many sperm heads, occasional sperm with short tails	Vasovasostomy
Copious, thick white toothpaste-like, water insoluble	No sperm	Vasoepididymostomy
Scant white thin fluid	No sperm	Vasoepididymostomy
Scant fluid, no granuloma at vasectomy site	No sperm	Vasoepididymostomy
Scant fluid, granuloma present at vasectomy site	Barbotage fluid reveals sperm	Vasovasostomy

Reproduced with permission from reference 23 © (2002) Elsevier Inc.

six sutures, for a total of 24 sutures (Figure 1). The dartos layer is approximated with interrupted 4-0 absorbable sutures and the skin with subcuticular sutures of 5-0 Monocryl® (Johnson and Johnson, New Brunswick, NJ).

Vasoepididymostomy

Microsurgical vasoepididymostomy

Microsurgical vasoepididymostomy is considered the most technically challenging type of surgery for the male reproductive system. In virtually no other operation are results so dependent upon the surgeon's technical expertise. Surgeons who perform vasoepididymostomy, therefore, must have extensive experience in microsurgical techniques and carry out the procedure frequently. The indications for performing vasoepididymostomy at the time of vasectomy reversal, based on gross appearance of the vasal fluid,²³ are reviewed in Table 1. Although occasional discrepancies exist between gross and microscopic findings, they correlate approximately 80% of the time. It is, however, essential to view the vasal fluid under the microscope, in order to determine whether to proceed with vasovasostomy or with vasoepididymostomy. For obstructive azoospermia that is not due to vasectomy or absence of the vas deferens, vasoepididymostomy is indicated when the testis biopsy reveals complete spermatogenesis and scrotal exploration reveals the absence of sperm in the vasal lumen.

Microsurgical end-to-side two-suture intussusception vasoepididymostomy

The intussusception technique, originally known as the three-suture triangulation technique, was

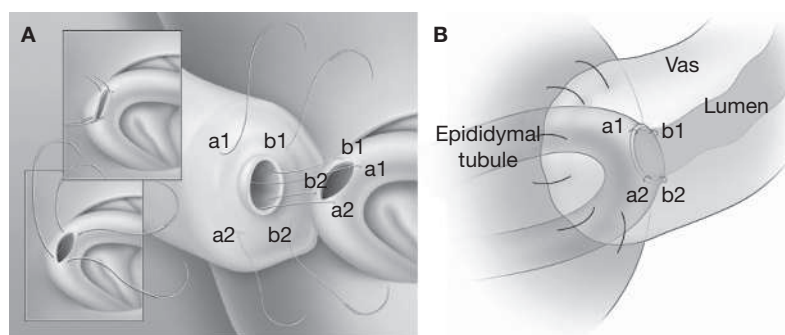


Figure 2 Microsurgical end-to-side two-suture intussusception vasoepididymostomy. **(A)** Two parallel sutures are placed in the selected epididymal tubule, oriented longitudinally, then the tubule is incised between the two needles (top inset). Once the epididymal tubule has been incised, the sutures are pulled through (bottom inset). The double-arm needles are placed in-to-out through the vasal lumen. The suture points are labeled to indicate where they run (a1 to a1, etc.). **(B)** Completed anastomosis. The suture points at the completed anastomosis are indicated by a1, a2, b1 and b2. Reproduced with permission from reference 7 © (2003) Elsevier Inc.

developed by Berger.²⁶ Marmar described a modified technique that consists of two sutures with transverse double-needle placement within the epididymal tubule.²⁷ At Cornell University, a longitudinal two-suture intussusception vasoepididymostomy approach (Figure 2A) was developed in order to further improve the procedure.⁷ With this method, four microdots are marked on the cut surface of the vas deferens and two parallel double-arm sutures are placed in the distended epididymal tubule; however, the needles are not pulled through. After the epididymal fluid is tested for sperm and aspirated into micropipettes for cryopreservation, the two needles within the epididymal tubule are pulled through, and all four

Table 2 Advantages and disadvantages of surgical techniques for sperm retrieval.

	Advantages	Disadvantages
Microsurgical epididymal sperm aspiration	Low complication rate if performed microsurgically Epididymal sperm have better motility than testicular sperm Large number of sperm can be harvested for cryopreservation of multiple vials in a single procedure	General anesthesia preferred Requires microsurgical skills Not indicated for nonobstructive azoospermia
Percutaneous epididymal sperm aspiration	No microsurgical skill required Local rather than general anesthesia Epididymal sperm have better motility than testicular sperm	Variable success in obtaining sperm Smaller quantity of sperm obtained than with microsurgical epididymal sperm aspiration Not indicated for nonobstructive azoospermia Complications include hematoma, pain and vascular injury to testes and epididymis
Testicular sperm aspiration	No microsurgical skill required Local rather than general anesthesia Can be used for obstructive azoospermia	Immature or immotile sperm Small quantity of sperm obtained Poor results in nonobstructive azoospermia Complications include hematoma, pain and vascular injury to testes and epididymis
Testicular sperm extraction	Low complication rate if performed microsurgically Preferred technique for nonobstructive azoospermia	Requires general anesthesia and microsurgical skills

Reproduced with permission from reference 23 © (2002) Elsevier Inc.

needles are placed through the vas lumen at the marked locations. Tying down the sutures allows the epididymal tubule to be intussuscepted into the vasal lumen, completing the anastomosis (Figure 2B). The patency rate with the longitudinal intussusception vasoepididymostomy approach was over 90% in a recent clinical series, and intussusception is the preferred method for all vasoepididymostomies.⁶

All successful vasovasostomy and vasoepididymostomy techniques rely on adherence to surgical principles that are universally applicable to anastomoses of all tubular structures: an accurate mucosa-to-mucosa approximation; leak-proof anastomosis; tension-free anastomosis; good blood supply; healthy mucosa and muscularis; and atraumatic anastomotic technique.

EPIDIDYMAL SPERM ASPIRATION

When to perform sperm extraction

Although most postvasectomy patients are candidates for microsurgical reconstruction, not all obstructive-azoospermic men can be managed surgically. In order that these men can become biological fathers, various sperm-retrieval techniques have been developed for use in conjunction with *in vitro* fertilization (IVF). Before the introduction of ICSI, sperm retrieval was performed with IVF and limited forms of micromanipulation, such as partial zona dissection. ICSI has now replaced all other types of assisted reproduction.

Congenital bilateral absence of the vas deferens (CBAVD) is an abnormality related to cystic fibrosis. In patients with mutations in the cystic fibrosis transmembrane conductance regulator (CFTR) gene, segments of the excurrent ductal system anywhere from the midportion of the epididymis to the seminal vesicles are missing.²⁸ Only a minority of patients with a CFTR gene mutation have enough healthy tissue for reconstruction to be feasible.²⁹ The majority of patients with CBAVD, therefore, will need epididymal sperm aspiration for IVF via ICSI.^{30–32} Before IVF is performed, it should be determined whether both partners are carriers of the CFTR gene mutation.

There are various surgical techniques for sperm retrieval; their advantages and disadvantages are summarized in Table 2. These techniques are also useful for intraoperative retrieval of sperm during reconstructive procedures such as vasoepididymostomy, which have failure rates high enough that intraoperative cryopreservation of sperm for a future IVF cycle should be considered, in the event that the reconstructive surgery is unsuccessful.

Sperm obtained from patients with chronically obstructed reproductive systems usually have poor motility and decreased fertilization capacity. The use of ICSI is essential to achieve optimal results in most cases. One notable exception is chronic obstruction secondary to previous vasectomy. Female partners of

men who underwent vasovasostomy more than 15 years after their initial vasectomy still achieved a natural pregnancy rate of 44%.²⁰ The sperm of patients with chronic epididymal obstruction in this setting will take longer to regain motility; however, even if natural conception does not occur, ejaculated sperm could be used for intrauterine insemination or ICSI.

Open epididymal tubule sperm retrieval technique

Microsurgical epididymal sperm aspiration can be employed either for intraoperative sperm retrieval at the time of vasoepididymostomy or as an isolated procedure in men with congenital absence of the vas deferens or unreconstructable obstructions.³³ Under the operating microscope, the epididymal tunic is incised and a dilated epididymal tubule is selected, isolated and incised with a 15° microknife (Figure 3A). The fluid is touched to a slide, a drop of saline or Ringer's solution is added, a cover slip is placed over the slide, and the fluid is immediately examined under a bench microscope. As soon as motile sperm are found, a dry micropipette is placed adjacent to the effluxing epididymal tubule (Figure 3B). A standard hematocrit pipette is less satisfactory, but can be used if a micropipette is not available. Sperm are drawn into the micropipette by simple capillary action. Negative pressure, as is generated by the action of an in-line syringe, should not be applied during sperm retrieval as this can disrupt the delicate epididymal mucosa. Two micropipettes can be employed simultaneously in order to increase the speed of sperm retrieval. The highest rate of flow is observed immediately following incision of the tubule. Progressively better-quality sperm are often found following the initial washout. Gentle compression of the testis and epididymis enhances flow from the incised tubule. With patience, 25–50 µl of highly concentrated epididymal fluid, containing approximately 75 million sperm, can be recovered. This is diluted in multiple aliquots of 2–3 ml of human tubal-fluid medium, so that there are 5–10 million sperm per ml. Those specimens not used immediately for ART are cryopreserved for possible future use. If no sperm are obtained, the epididymal tubule and tunic are closed with 10-0 and 9-0 monofilament nylon sutures, respectively, and an incision is made more proximally in the epididymis, or even at the level of the efferent ductules, until motile sperm are obtained.

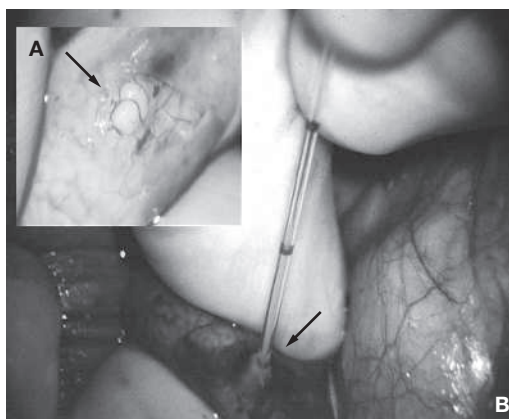


Figure 3 Microsurgical epididymal sperm aspiration (A) Selection and isolation of dilated tubule (×10). (B) Aspiration of sperm into micropipette by capillary action (×15). Reproduced with permission from reference 23 © (2002) Elsevier Inc.

Box 1 Causes of nonobstructive azoospermia.

Congenital and developmental

Genetic

- Karyotypic abnormalities
- Y-chromosomal microdeletions

Testicular

- Cryptorchidism
- Torsion
- Bilateral anorchia

Endocrinologic

- Deficiencies of gonadotropin-releasing hormone agonist, luteinizing hormone, and follicle-stimulating hormone
- Excess of androgen, estrogen, prolactin, glucocorticoid
- Thyroid abnormalities
- Receptor abnormalities

Varicocele

Acquired

Environmental hazards

- Radiation
- Heat or thermal injury

Iatrogenic

- Ischemic atrophy
- Radiotherapy
- Chemotherapy

Diseases

- Neoplastic diseases
- Infections or inflammatory causes
- Systemic illness

Drugs or gonadotoxins

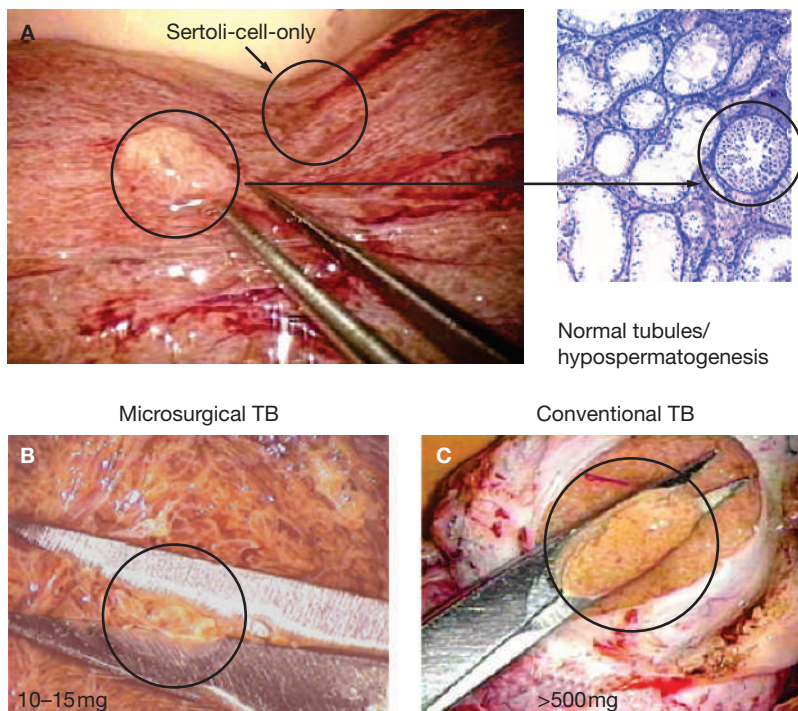


Figure 4 Microdissection testicular sperm extraction. (A) Comparison of full, white sperm-containing tubules (to left) with stringy-appearing, yellowish Sertoli-cell-only tubules (right) ($\times 25$). An example is provided of what a sample might look like under microscopic histologic examination. (B) Excision of full tubules under microscopic assistance ($\times 25$). (C) Conventional testis biopsy. Abbreviation: TB, testis biopsy. Reproduced with permission from reference 23 © (2002) Elsevier Inc.

Success of sperm extraction techniques

Sperm retrieval from the epididymides of men with obstructive azoospermia is possible in over 99% of patients when performed by experienced microsurgions.^{34,35} Success rates such as these are possible even if multiple prior procedures have been performed and extensive scarring is present in the scrotum. If the epididymis is obliterated because of previous procedures or infection, the most proximal efferent ductules of the testis can be exposed by reflection of the caput epididymis to uncover the 7 to 11 dilated tubules. One should be able to aspirate sperm from at least one of these tubules.

In a study of 76 attempts at sperm retrieval using MESA and ICSI in men with obstructive azoospermia, clinical pregnancies were detected by a fetal heartbeat after 75% of attempts, with ongoing pregnancy or delivery achieved for 64% of attempts.³⁶ For men with CBAVD, the success rate is even higher.³⁷ Optimal fertilization and pregnancy rates are obtained with a technique of aggressive immobilization of

spermatozoa prior to ICSI. It is possible that aggressive immobilization acts by enhancing sperm membrane permeability to improve the ability of immature spermatozoa to fertilize oocytes.³⁸ The teamwork and collaborative effort of reproductive endocrinologists, embryologists, and male reproductive surgeons is of paramount importance for successful results.

NONOBSTRUCTIVE AZOOSPERMIA

Nonobstructive azoospermia (NOA), or testicular failure, is the most challenging type of male-factor infertility to manage. Various conditions that can lead to NOA have been identified (Box 1). While some of the underlying causes of NOA might be reversible to a degree, advanced ART techniques are needed for the majority of patients with this condition. With the advent of ART, particularly ICSI in conjunction with sperm obtained via testicular sperm extraction (TESE), many of these men are now able to father their own biological children. However, there remain subgroups of 20–40% of patients with NOA who, despite the advent of ICSI and advances in microsurgical sperm extraction techniques, are not able to have sperm retrieved for assisted reproduction.³⁹ In these cases, the couples should consider donor-sperm fertilization or adoption as alternatives.

Testicular-sperm extraction

Testicular sperm can be found within the testicular tissue of many men with NOA. The optimal technique of sperm extraction would be minimally invasive and avoid destruction of testicular function, without compromising the chance of retrieving enough spermatozoa with which to perform ICSI.

Microdissection testicular sperm extraction

Microdissection TESE is an advanced version of TESE that applies microsurgical techniques to the retrieval of sperm from the seminiferous tubules. Although microdissection TESE is not a minimally invasive technique, it results in the removal of a minimal amount of testicular tissue with maximal sperm yield, and minimizes the negative impact on testicular function. This method was developed by Schlegel,⁴⁰ and is an effective method for the retrieval of sperm from men with NOA, for use in ICSI. The seminiferous tubules from different areas of the testis are often associated with different states

of maturation of spermatogenesis. In other words, in some areas of the testis, the Sertoli-cell-only pattern might be present, whereas other areas might show maturation arrest, hypospermatogenesis, or even normal spermatogenesis. Under the operating microscope ($\times 25$), an experienced surgeon can usually distinguish between 'more active' and 'less active' seminiferous tubules by their appearance; tubules that appear full, opaque, and are larger in comparison to other tubules are more likely to contain sperm (Figures 4A and 4B).

The conventional TESE technique requires multiple, blind testis biopsies with excision of large volumes (>500 mg) of testicular tissue, which can result in permanent damage to the testis (Figure 4C). The microdissection TESE technique of sequential excision of microdissected seminiferous tubules (10–15 mg, or 2 mm in length, of seminiferous tubule) has been shown to be more successful, compared with the results achieved by conventional TESE, or random biopsies of testicular tissue. In a sequential series of TESE attempts, Schlegel showed that sperm-retrieval rates improved from 45% (10 out of 22 patients) with conventional TESE to 63% (17 out of 27 patients) with microdissection TESE. Microdissection samples yielded an average of 160,000 spermatozoa per 9.4 mg sample, whereas only 64,000 spermatozoa were found in an average 720 mg conventional biopsy sample ($P < 0.05$ for all comparisons).⁴¹

Outcomes of testicular sperm extraction

By using microdissection TESE in men with NOA, a sufficient number of spermatozoa can be retrieved with a minimal amount of testicular tissue being excised. In addition, optical magnification allows for the minimal disturbance of the testicular blood supply.⁴² Microdissection TESE is a more efficient technique for sperm retrieval in men with NOA than conventional TESE, and results in less postoperative intratesticular scarring.⁴³

The likelihood of sperm retrieval in patients with nonobstructive azoospermia can be estimated on the basis of the most advanced pattern of spermatogenesis (not the most predominant pattern) seen on histopathology, if a previous testis biopsy has been performed.⁴⁴ In men with at least one area of hypospermatogenesis, microdissection TESE resulted in successful sperm retrieval in 81% of patients. In men where the

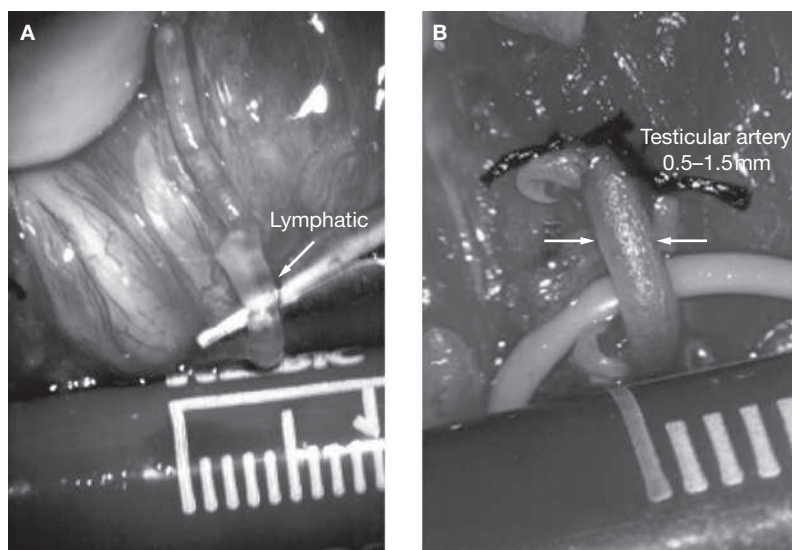


Figure 5 Microsurgical varicocelectomy ($\times 25$). (A) Lymphatic vessel. (B) Testicular artery. Reproduced with permission from reference 23 © (2002) Elsevier Inc.

most advanced form of spermatogenesis was maturation arrest, the retrieval rate was 44%. Even those who exhibited a Sertoli-cell-only pattern had sperm retrieved in 41% of cases.⁴³

In an extension of the 1999 study by Palermo *et al.*,⁴⁵ the team at Cornell University made 684 attempts at sperm retrieval, using microdissection TESE for men with NOA, with encouraging results. Sperm were retrieved from 59% of the men. The fertilization rate from subsequent ICSI procedures using the extracted sperm was 59% per injected oocyte, and clinical pregnancy, as defined by detection of a fetal heartbeat, was achieved in 48% of the cycles in which sperm were retrieved (PN Schlegel, unpublished data).

Varicocelectomy

Varicocelectomy is the most common procedure for male infertility. Varicoceles are found in approximately 10–15% of unmarried, male military recruits,⁴⁶ in 35% of infertile men who have never fathered a child, and in 81% of men who were once fertile, as proven by previous conception, but who are now infertile (secondary infertility).⁴⁷ Repair of varicocele for treatment of male infertility is controversial;⁴⁸ however, any studies that have not shown an improved pregnancy rate after varicocele repair were small, were not stratified by grade of varicocele, and did not control for type of repair technique.⁴⁹

Table 3 Techniques of varicocelectomy and potential complications.

Technique	Artery preserved	Incidence of hydrocele (%)	Failure rate (%)	Potential for serious morbidity
Microscopic inguinal	Yes	<1	<1	No
Conventional inguinal	No	3–30	5–15	No
Retroperitoneal	No	7	15–25	No
Laparoscopic	Yes	12	5–15	Yes

Reproduced with permission from reference 23 © (2002) Elsevier Inc.

It is possible that varicocelectomy can halt further damage to testicular function and improve spermatogenesis, as well as enhancing Leydig-cell function (as reflected by an increase in postoperative serum testosterone levels in infertile men).⁵⁰ Urologists might, therefore, have a valuable role in preventing future infertility and androgen deficiency^{51,52} in aging men, and this underscores the importance of using a varicocelectomy technique that minimizes the risk of complications and varicocele recurrence.

Preferred approaches: microsurgical inguinal and subinguinal operations

The advantages of microsurgical techniques over other approaches to varicocele repair (e.g. open surgical, laparoscopic, and percutaneous techniques) are the reliable identification and preservation of the testicular artery or arteries, cremasteric artery or arteries, and lymphatic channels, as well as the reliable identification of all internal spermatic veins and gubernacular veins. Delivery of the testis through the subinguinal incision allows inspection of the gubernacular veins, assuring direct visual access to all possible routes of venous return, including external spermatic, cremasteric, and gubernacular veins.⁵³ Postoperatively, venous return is via the deferential (vasal) veins, which drain into the internal pudendal veins and usually have competent valves.

The application of microsurgical techniques^{53,54} to varicocelectomy has resulted in a substantial reduction in the incidence of hydrocele formation. This is because the lymphatic vessels can be more easily identified and preserved (Figure 5A). Furthermore, the use of magnification enhances the surgeon's ability to identify and preserve the 0.5–1.5 mm testicular artery⁵⁵ (Figure 5B), thus avoiding the complications of atrophy or azoospermia.

Varicocele outcomes

The goals of varicocele repair are to relieve pain in symptomatic cases and to improve semen parameters, testicular function, and pregnancy rates in couples with male-factor infertility associated with varicocele. Studies have shown that varicocele repair can improve all three of these in infertile men,^{46,56} with a significant improvement in semen analysis seen in 60–80% of men.⁵⁷ Varicocele repair in young men might be able to prevent infertility and androgen deficiency later in life.⁵⁰

The clinical outcomes of varicocelectomy are also related to the size of the varicocele. Repair of large varicoceles results in a significantly greater improvement in semen quality than repair of small varicoceles.^{58,59} In addition, large varicoceles are associated with greater preoperative impairment in semen quality than small varicoceles; consequently, overall pregnancy rates are similar regardless of varicocele size. In the presence of small (grade I) varicoceles along with larger (grade II and III), contralateral varicoceles, greater improvement in semen parameters can be expected if repair is performed bilaterally, rather than only the larger side being repaired.⁶⁰ Some evidence suggests that the younger the patient is at the time of varicocele repair, the greater the improvement after repair and the more likely the testis is to recover from varicocele-induced injury.^{61–63} Testicular artery ligation and post-varicocelectomy hydrocele formation may be associated with poor postoperative results.

In a controlled trial of varicocele repair in infertile men that compared surgery with no surgery, the surgery group had a pregnancy rate of 44% at 1 year, compared with 10% in the no-surgery group. Using the microsurgical technique in 1,500 men who underwent varicocelectomy, the pregnancy rate in couples was

43% after 1 year and 69% after 2 years, compared to 16% in couples with men who declined surgery and instead had hormone treatment or used ART. There have been only 14 recurrences (1%), no reports of hydrocele or testicular atrophy,⁵³ and only a 1% incidence of inadvertent unilateral testicular artery ligation.⁶⁴

The most common complications of varicocelectomy are hydrocele formation, varicocele recurrence, and testicular artery injury (Table 3). Use of the operating microscope allows for reliable identification of spermatic cord lymphatics, internal spermatic veins and venous collaterals, and the testicular artery or arteries; the incidence of such complications can, therefore, be significantly reduced. Delivery of the testis through a small subinguinal incision provides direct visual access to all possible avenues of testicular drainage to ensure complete ligation. Failure to deliver the testis might result in varicocele recurrence in 7% of patients because of scrotal collaterals.⁶⁵ Additional benefits of delivery of the testis include the identification of otherwise-undetected small testicular tumors and previously undiagnosed epididymal or vasal obstructions (M Goldstein, unpublished data).

Advocates of nonmicrosurgical techniques contend that the deferential (vasal) artery and, if preserved, the cremasteric artery, will ensure blood supply to the testes that is adequate to prevent atrophy.^{66,67} Anatomic studies, however, have shown that the diameter of the testicular artery is greater than the diameter of the deferential artery and cremasteric artery combined.⁵⁵ The testicular artery is the main blood supply to the testes. At the very least, it is inarguable that ligation of the testicular artery is unlikely to enhance testicular function. Microsurgical varicocelectomy is a safe and effective approach to varicocele repair, and preserves testicular function, improves semen quality and pregnancy rates in a significant number of couples. Ultimately, the ideal intervention for varicoceles can only be determined by a large, prospective, randomized and controlled study using a microsurgical, artery and lymphatic-sparing technique.

CONCLUSION

Very few medical fields have changed as dramatically over the past decade as reproductive medicine, particularly in terms of the diagnostic and treatment strategies for male infertility. These advances include ICSI, refined microsurgical

reconstructive techniques (vasovasostomy and vasoepididymostomy), microsurgical techniques for surgical sperm retrieval from the epididymis and testis, and microsurgical varicocele repair. These techniques remain the safest and most cost-effective ways of treating infertile men, and, perhaps more importantly for the couples involved, many of these techniques enable couples to conceive naturally.

KEY POINTS

- Successful vasovasostomy is predicated on the basic surgical principles of a tension-free, watertight anastomosis with mucosa-to-mucosa apposition.
- Performing vasovasostomy or vasoepididymostomy is more cost-effective for achieving pregnancy than assisted reproductive technologies that use sperm aspiration
- Vasoepididymostomy is the most technically difficult of all microsurgical procedures, and should only be performed by experienced microsurgeons
- Varicocele is a risk factor for impaired spermatogenesis and Leydig-cell function, and varicocele repair can improve testicular function
- Ligation of the testicular artery during varicocele repair is not likely to improve testicular function
- Preservation of lymphatic drainage during varicocele repair decreases the risk of postoperative hydrocele

References

- 1 US Department of Health and Human Services, Centers for Disease Control and Prevention (2005) 2003 Assisted Reproductive Technology (ART) Report [<http://www.cdc.gov/ART/ART2003>] (accessed 2 June 2006)
- 2 Matthews GJ *et al.* (1995) Patency following microsurgical vasoepididymostomy and vasovasostomy: temporal considerations. *J Urol* **154**: 2070–2073
- 3 Goldstein M *et al.* (1998) Microsurgical vasovasostomy: the microdot technique of precision suture placement. *J Urol* **159**: 188–198
- 4 McCallum S *et al.* (2002) Comparison of triangulation end-to-side and conventional end-to-side microsurgical vasoepididymostomy in rats. *J Urol* **167**: 2284–2288
- 5 Goldstein M *et al.* (2002) Ultra-precise Multi-layer microsurgical vasovasostomy: tricks of the trade. Abstracts of the American Urological Association Annual Meeting, May 25–30, 2002, Orlando, Florida, USA [abstract # V641]. *J Urol* **167** (Suppl 4): S1–S425
- 6 Chan PT *et al.* (2005) Prospective analysis of the post-operative outcomes of microsurgical intussusception vasoepididymostomy. *BJU Int* **96**: 598–601

- 7 Chan PT *et al.* (2003) Microsurgical vasoepididymostomy: a randomized study of the different intussusception techniques in rats. *J Urol* **169**: 1924–1929
- 8 Goldstein M *et al.* (2003) Microsurgical intussusception vasoepididymostomy: tricks of the trade [video]. *J Urol* **169**: V-1450
- 9 Matthews GJ *et al.* (1998) Induction of spermatogenesis and achievement of pregnancy after microsurgical varicoeleotomy in men with azoospermia and severe oligoasthenospermia. *Fertil Steril* **70**: 71–75
- 10 Chan PT and Goldstein M (2002) Medical background on varicocele. *Drugs Today (Barc)* **38**: 59–67
- 11 Chan PT and Schlegel PN (2000) Diagnostic and therapeutic testis biopsy. *Curr Urol Rep* **1**: 266–272
- 12 Sheynkin YR *et al.* (1998) Microsurgical repair of iatrogenic injury to the vas deferens. *J Urol* **159**: 139–141
- 13 Hendin BN *et al.* (1992) Surgical reconstruction of iatrogenic injury to the vas deferens. *Am Fertil Soc 48th Annual Meeting 1992 October 31–November 5, New Orleans* **140**: 1545–1548
- 14 Donovan JF Jr *et al.* (1998) Comparison of microscopic epididymal sperm aspiration and intracytoplasmic sperm injection/in-vitro fertilization with repeat microscopic reconstruction following vasectomy: is second attempt vas reversal worth the effort? *Hum Reprod* **13**: 387–393
- 15 Pavlovich CP and Schlegel PN (1997) Fertility options after vasectomy: a cost-effectiveness analysis. *Fertil Steril* **67**: 133–141
- 16 Kolettis PN and Thomas AJ (1997) Vasoepididymostomy for vasectomy reversal: a critical assessment in the era of intracytoplasmic sperm injection. *J Urol* **158**: 467–470
- 17 Silber SJ (1977) Microscopic vasectomy reversal. *Fertil Steril* **28**: 1191–1202
- 18 Belker AM *et al.* (1991) Results of 1,469 microsurgical vasectomy reversals by the Vasovasostomy Study Group. *J Urol* **145**: 505–511
- 19 Silber SJ (1989) Results of microsurgical vasoepididymostomy: role of epididymis in sperm maturation. *Hum Reprod* **4**: 298–303
- 20 Schiff J *et al.* (2005) Outcome and late failures compared in 4 techniques of microsurgical vasoepididymostomy in 153 consecutive men. *J Urol* **174**: 651–655
- 21 Boorjian S *et al.* (2004) The impact of obstructive interval and sperm granuloma on outcome of vasectomy reversal. *J Urol* **171**: 304–306
- 22 Meinertz H *et al.* (1990) Antisperm antibodies and fertility after vasovasostomy: a follow-up study of 216 men. *Fertil Steril* **54**: 315–321
- 23 Goldstein M (2002) Surgical management of male infertility and other scrotal disorders. In *Campbell's Urology*, edn 8 1533–1587 (Eds Walsh PC *et al.*) Philadelphia: WB Saunders
- 24 Fuchs EF and Burt RA (2002) Vasectomy reversal performed 15 years or more after vasectomy: correlation of pregnancy outcome with partner age and with pregnancy results of in vitro fertilization with intracytoplasmic sperm injection. *Fertil Steril* **77**: 516–519
- 25 Fenster H and McLoughlin MG (1981) Vasovasostomy—microscopic versus macroscopic techniques. *Arch Androl* **7**: 201–204
- 26 Berger RE (1998) Triangulation end-to-side vasoepididymostomy. *J Urol* **159**: 1951–1953
- 27 Marmar JL (2000) Modified vasoepididymostomy with simultaneous double needle placement, tubulotomy and tumular invagination. *J Urol* **163**: 483–486
- 28 Daudin M *et al.* (2000) Congenital bilateral absence of the vas deferens: clinical characteristics, biological parameters, cystic fibrosis transmembrane conductance regulator gene mutations, and implications for genetic counseling. *Fertil Steril* **41**: 1164–1174
- 29 Stuhmann M and Dörk T (2000) CFTR mutations and male infertility. *Andrologia* **32**: 71–83
- 30 Silber SJ *et al.* (1990) Congenital absence of the vas deferens: the fertilization capacity of human epididymal sperm. *N Engl J Med* **323**: 1788–1792
- 31 Schlegel PN *et al.* (1994) Epididymal micropuncture with IVF for treatment of surgically unreconstructable vasal obstruction. *Fertil Steril* **61**: 895–901
- 32 Temple-Smith PD *et al.* (1985) Human pregnancy by *in vitro* fertilization (IVF) using sperm aspirated from the epididymis. *J In Vitro Fert Embryo Transf* **2**: 119–122
- 33 Matthews GJ and Goldstein M (1996) A simplified technique of epididymal sperm aspiration. *Urology* **47**: 123–125
- 34 Schlegel PN *et al.* (1995) Micropuncture retrieval of epididymal sperm with *in vitro* fertilization: importance of *in vitro* micromanipulation techniques. *Urology* **46**: 238–241
- 35 Nudell DM *et al.* (1998) The mini-micro-epididymal sperm aspiration for sperm retrieval: a study of urological outcomes. *Hum Reprod* **13**: 1260–1265
- 36 Janzen N *et al.* (2000) Use of electively cryopreserved microsurgically aspirated epididymal sperm with IVF and intracytoplasmic sperm injection for obstructive azoospermia. *Fertil Steril* **74**: 696–701
- 37 Anger JT *et al.* (2004) Sperm cryopreservation and *in vitro* fertilization/Intracytoplasmic sperm injection in men with congenital bilateral absence of the vas deferens: a success story. *Fertil Steril* **82**: 1452–1454
- 38 Palermo GD *et al.* (1996) Aggressive sperm immobilization prior to intracytoplasmic sperm injection with immature spermatozoa improves fertilization and pregnancy rates. *Hum Reprod* **11**: 1023–1029
- 39 Chan PT and Schlegel PN (2000) Non-obstructive azoospermia. *Curr Opin Urol* **10**: 617–624
- 40 Schlegel PN, Li PS (1998) Microdissection TESE: sperm retrieval in non-obstructive azoospermia. *Hum Reprod Update* **4**: 439
- 41 Schlegel PN (1999) Testicular sperm extraction: microdissection improves sperm yield with minimal tissue excision. *Hum Reprod* **14**: 131–135
- 42 Dardashti K *et al.* (2000) Microsurgical testis biopsy: a novel technique for retrieval fo testicular tissue. *J Urol* **163**: 1206–1207
- 43 Ramasamy R *et al.* (2005) Structural and functional changes to the testis after conventional versus microdissection testicular sperm extraction. *Urology* **65**: 1190–1194
- 44 Su L-M *et al.* (1999) Testicular sperm extraction with intracytoplasmic sperm injection for nonobstructive azoospermia: testicular histology can predict success of sperm retrieval. *J Urol* **161**: 112–116
- 45 Palermo GD *et al.* (1999) Fertilization and pregnancy outcome with Intracytoplasmic sperm injection for azoospermic men. *Hum Reprod* **14**: 741–748
- 46 Thomas AM and Fariss BL (1979) The prevalence of varicoceles in a group of healthy young men. *Mil Med* **144**: 181–182
- 47 Gorelick JL and Goldstein M (1993) Loss of fertility in men with varicocele. *Fertil Steril* **59**: 613–616
- 48 Evers JL and Collins JA (2003) Assessment of efficacy of varicocele repair for male subfertility: a systematic review. *Lancet* **361**: 1849–1852

- 49 Ficarra V *et al.* (2006) Treatment of varicocele in subfertile men: the Cochrane review – a contrary opinion. *Eur Urol* **49**: 258–263
- 50 Su L-M *et al.* (1995) The effect of varicocelectomy on serum testosterone levels in infertile men with varicoceles. *J Urol* **154**: 1752–1755
- 51 Younes AK (2003) Improvement of sexual activity, pregnancy rate, and low plasma testosterone after bilateral varicocelectomy in impotence and male infertility patients. *Arch Androl* **49**: 219–228
- 52 Shah JB *et al.* (2005) Is there an association between varicoceles and hypogonadism in infertile men? *J Urol* **173**: 449
- 53 Goldstein M *et al.* (1992) Microsurgical inguinal varicocelectomy with delivery of the testis: an artery and lymphatic sparing technique. *J Urol* **148**: 1808–1811
- 54 Marmar JL and Kim Y (1994) Subinguinal microsurgical varicocelectomy: a technical critique and statistical analysis of semen and pregnancy data. *J Urol* **152**: 1127–1132
- 55 Raman JD and Goldstein M (2004) Intraoperative characterization of arterial vasculature in spermatic cord. *Urology* **64**: 561–564
- 56 Madgar I *et al.* (1995) Controlled trial of high spermatic vein ligation for varicocele in infertile men. *Fertil Steril* **63**: 120–124
- 57 Kim ED *et al.* (1999) Varicocele repair improves semen parameters in azoospermic men with spermatogenic failure. *J Urol* **162**: 737–740
- 58 Steckel J *et al.* (1993) Influence of varicocele size on response to microsurgical ligation of the spermatic veins. *J Urol* **149**: 769–771
- 59 Jarow JP *et al.* (1996) Seminal improvement following repair of ultrasound detected subclinical varicoceles. *J Urol* **155**: 1287–1290
- 60 Scherr D and Goldstein M (1999) Comparison of bilateral versus unilateral varicocelectomy in men with palpable bilateral varicoceles. *J Urol* **162**: 85–88
- 61 Hadziselimovic F *et al.* (1989) Testicular and vascular changes in children and adults with varicocele. *J Urol* **142**: 583–585
- 62 Kass EJ and Belman AB (1987) Reversal of testicular growth failure by varicocele ligation. *J Urol* **137**: 475–476
- 63 Lemack GE *et al.* (1998) Microsurgical repair of the adolescent varicocele. *J Urol* **160**: 179–181
- 64 Chan PT *et al.* (2005) Incidence and postoperative outcomes of accidental ligation of the testicular artery during microsurgical varicocelectomy. *J Urol* **173**: 482–484
- 65 Murray RR Jr. *et al.* (1986) Comparison of recurrent varicocele anatomy following surgery and percutaneous balloon occlusion. *J Urol* **135**: 286–289
- 66 Matsuda T *et al.* (1993) Should the testicular artery be preserved at varicocelectomy? *J Urol* **149**: 1357–1360
- 67 Atassi O *et al.* (1995) Testicular growth after successful varicocele correction in adolescents: comparison of artery sparing techniques with the Palomo procedure. *J Urol* **153**: 482–483

Acknowledgments

Dr Tanrikut is supported by The Frederick J and Theresa Dow Wallace Fund of the New York Community Trust.

Competing interests

The authors declared they have no competing interests.

INHERITANCE OF VARICOCELES

JAY D. RAMAN, KONSTANTIN WALMSLEY, AND MARC GOLDSTEIN

ABSTRACT

Objectives. To evaluate the inheritance of varicoceles through examination of first-degree relatives of patients with known varicoceles.

Methods. A total of 44 patients with a known varicocele had available first-degree relatives ($n = 62$) examined for the presence of a varicocele between October 1997 and November 2003. An additional cohort of 263 men presenting for vasectomy reversal without a history of subfertility or varicocele was used as the control group. Varicocele grade and the presence of bilateral varicoceles were examined as predictive factors for inheritance.

Results. Of the 62 first-degree relatives of patients with a known varicocele, 35 (56.5%) had a clinically palpable varicocele on physical examination. This was significantly greater than the 18 (6.8%) of 263 men in the control group ($P < 0.0001$). Of the first-degree relatives, 20 (74%) of 27 brothers, 13 (41%) of 32 fathers, and 2 (67%) of 3 sons had palpable varicoceles. Neither varicocele grade nor bilaterality was predictive of inheritance in these first-degree relatives.

Conclusions. The increase in varicocele prevalence is significant in the first-degree relatives (particularly brothers) of patients with known varicoceles. Given the detrimental effect of varicoceles on spermatogenesis and steroidogenesis, patients should be counseled about this increased risk in male family members. UROLOGY 65: 1186–1189, 2005. © 2005 Elsevier Inc.

Varicoceles are detected in approximately 15% of the general male population, with the prevalence increasing to 35% of men presenting with primary infertility, and up to 80% of men with secondary infertility.^{1,2} The etiology of varicoceles is likely multifactorial. Potential causes include the length of the gonadal vessels, the absence of valves within the gonadal veins, renal vein to inferior vena cava pressure gradients, and the angle of insertion of the left gonadal vein into the left renal vein.^{3,4}

Animal and human studies have confirmed that varicoceles are associated with a progressive, duration-dependent decline in testicular function.^{1,2,5,6} The most likely mechanism is an elevation of testicular temperature due to an impaired counter-current heat exchange mechanism.^{7,8} MacLeod⁹ first described the triad of oligospermia, impaired

motility, and an increased percentage of immature forms to be characteristic of semen analyses in men with a varicocele. Johnson *et al.*¹⁰ further showed that 70% of healthy, asymptomatic military recruits with a palpable varicocele had an abnormal semen analysis. Varicocele repair halts further testicular damage, and in most men, results in an improvement in spermatogenesis, as well as enhanced Leydig cell function.^{11–13}

Despite the relatively high prevalence of varicoceles in the general population, as well as its association with impaired spermatogenesis and steroidogenesis, a paucity of information is available regarding the potential inheritance patterns of this condition. In the present study, we identified and examined the first-degree relatives of men with known varicoceles to determine the potential for inheritance better. Varicocele grade and the presence of bilateral varicoceles were further examined as possible predictive factors for inheritance within first-degree relatives.

MATERIAL AND METHODS

PATIENT SELECTION

We retrospectively reviewed the charts of men presenting to a tertiary care university center between October 1997 and

From the Center for Male Reproductive Medicine and Microsurgery, Department of Urology and Cornell Institute of Reproductive Medicine, New York Presbyterian Hospital, Weill-Cornell University Medical Center, New York, New York; and Population Council, Center for Biomedical Research, New York, New York

Reprint requests: Marc Goldstein, M.D., New York-Presbyterian Hospital, 525 East 68th Street, Starr 900, New York, NY 10021. E-mail: mgoldst@med.cornell.edu

Submitted: August 28, 2004, accepted (with revisions): December 22, 2004

TABLE I. Varicocele characteristics in primary patients, first-degree relatives, and control population

Cohort	Patients (n)	Varix (%)	Unilateral (L/R)	Bilateral	Grade I	Grade II	Grade III	Mean Grade
Primary	44	44/44 (100%)	16 (16/0)	28	16	18	38	2.3
First-degree relative	62	35/62 (56.5%)*	20 (19/1)	15	16	17	17	2.0
Control	263	18/263 (6.8%)	13 (12/1)	5	0	10	13	2.6

KEY: L/R = left/right.

* $P < 0.0001$ compared with control population.

November 2003 and identified those patients diagnosed with a palpable varicocele during an evaluation of subfertility. Of these men, 44 agreed to have their available first-degree relatives contacted for screening of varicoceles. Of the 106 first-degree relatives contacted, 62 (58.5%) elected to participate in this study. All first-degree relatives included in this study were asymptomatic and had neither a history of infertility nor a prior diagnosis of a varicocele. All participants provided informed consent per the Helsinki guidelines. The institutional review board of the New York Presbyterian Hospital-Weill Medical College of Cornell University approved this study.

A cohort of 263 consecutive men who presented to this same tertiary care university center between 1984 and 1998 for vasectomy reversal without a history of subfertility or a varicocele were used as a control population. All patients in the control group had undergone an identical rigorous physical examination by the same urologist as the study population.

PHYSICAL EXAMINATION

Physical examination of the scrotum and its contents was performed in all cases by a single urologist. The patients were examined in a warm room in the supine and standing positions, both with and without the Valsalva maneuver. Testicular volume, consistency, and the presence of varicoceles were assessed in each patient. The severity of the varicoceles was classified by a standard grading system. Grade I varicoceles were small and palpated only with the Valsalva maneuver, grade II were medium and palpable only in the standing position, and grade III were large and easily visualized through the scrotal skin without the Valsalva maneuver.

STATISTICAL ANALYSIS

Excel 2000 software (Microsoft, Redmond, Wash) and Statistical Analysis System, version 9.1, for Windows (SAS Institute, Cary, NC) were used to perform all statistical calculations, with $P < 0.05$ considered statistically significant. The chi-square test was used to compare the prevalence of varicoceles in our first-degree relative population and our control population. Multivariate logistic regression analysis was used to evaluate whether varicocele grade or the presence of bilaterality was predictive of inheritance. Finally, 95% confidence intervals were calculated to assess the precision of the obtained estimates.

RESULTS

The characteristics of the study participants are presented in Table I.

PRIMARY PATIENTS

The mean age of the 44 primary patients with a known palpable varicocele was 29.1 ± 11.6 years (range 14 to 77). Of the 44 men, 16 had a uni-

lateral varicocele (all left), and 28 had bilateral palpable varicoceles. More than 50% of the palpable varicoceles were grade III, with left-sided varicoceles averaging a grade of 2.8 and right averaging a grade of 1.5.

FIRST-DEGREE RELATIVES

The mean age for the 62 first-degree relatives was 42.7 ± 16.2 years (range 15 to 77). Of these 62 men, 35 (56.5%) had a palpable varicocele on physical examination. Among the first-degree relatives, 20 (74%) of 27 brothers, 13 (40.6%) of 32 fathers, and 2 (67%) of 3 sons had palpable varicoceles. Nineteen men had a unilateral left varicocele, 1 a unilateral right varicocele, and 15 bilaterally palpable varicoceles. One third of the palpable varicoceles were grade III, with left-sided varicoceles averaging a grade of 2.3 and the right averaging 1.4.

CONTROL PATIENTS

The mean age of the 263 men used as a control population for the prevalence of varicoceles was 50.3 ± 7.1 years (range 34 to 76). Of these 263 men who presented without a known history of varicoceles, 18 (6.8%) had a palpable varicocele on physical examination. Of the 18 patients, 12 had a unilateral left varicocele, 1 a unilateral right varicocele, and 5 bilaterally palpable varicoceles. No grade I varicoceles were identified in this group of patients; the distribution of grade II and III varicoceles (mean grade 2.6) was relatively equal.

PREVALENCE OF VARICOCELES

Compared with our control population (6.8%), the prevalence of palpable varicoceles in the first-degree relatives (56.5%) of patients with known varicoceles was eightfold greater ($P < 0.0001$).

PREDICTIVE FACTORS FOR INHERITANCE

Unilateral Versus Bilateral. Of 25 first-degree relatives of primary patients with a unilateral varicocele, 14 (56.0%) also had a varicocele, and 21 (56.8%) of 37 first-degree relatives of primary patients with bilateral varicoceles had palpable varicoceles ($P = 0.95$, chi-square test). After adjust-

ment for the varicocele grade status and age of the primary patient in a logistic regression model, this difference remained nonsignificant (odds ratio 1.1; 95% confidence interval 0.4 to 3.5; $P = 0.85$).

Varicocele Grade. In the consideration of varicocele grade, the greatest observed varicocele grade in the primary patients was used. Seven (63.6%) of 11 first-degree relatives of primary patients with a grade II varicocele had a palpable varicocele compared with 28 (54.9%) of 51 first-degree relatives of primary patients with a grade III varicocele ($P = 0.60$, chi-square test). After adjustment for bilateral status and age of the primary patient in the logistic regression model, this difference remained nonsignificant (odds ratio 0.8; 95% confidence interval 0.2 to 3.6; $P = 0.77$).

COMMENT

Varicoceles have been described in the medical literature since the first century. Most of the studies of varicoceles have focused on its pathophysiology, as well as on the methods and results of repair.^{11–15} The heredity of varicoceles and the potential transmission to first-degree relatives has rarely been addressed.

To our knowledge, this study is the largest to date to evaluate the inheritance of varicoceles. We found that more than 50% of first-degree relatives of patients with a varicocele also had a palpable varicocele. This was eightfold greater than in our control population of patients, who had a 6.8% incidence, as well as substantially greater than the reported incidence of 10% to 15% in multiple other large series.^{1,2,16} In general, the varicoceles were smaller in the first-degree relatives than in our primary patient population (mean 2.0 versus 2.3, respectively). In addition, fewer grade III varicoceles were noted in the first-degree relatives than in the primary patients (34% versus 53%, respectively). Neither of these two observations achieved statistical significance. We also found that neither the varicocele grade nor the presence of bilateral varicoceles in our primary patient population was predictive of inheritance in the first-degree relatives.

Because the numbers of the subgrouped relatives (father, brothers, sons) examined was relatively small, it was difficult to generalize trends of inheritance within each group. Of particular note, however, was the observation that more than 70% of brothers of men with varicoceles also had an asymptomatic, palpable varicocele.

The present study had a few limitations. First, we acknowledge that the 60% response rate of first-degree relatives, and the absence of grade I varicoceles in the control population contributed some component of a selection and screening bias to the study. A prospective, blinded study would limit

some of these confounding variables and is being planned for the future. Second, we understand that our control group may have had a lower prevalence of varicoceles than the general population, because these men all had prior proven fertility. A comparison with the greatest reported incidence of 15% in other series, however, still revealed an almost fourfold increase within the first-degree relatives.

Currently, no recommendations are available regarding the counseling of brothers, sons, or fathers of men with a palpable varicocele. To date, no evidence has suggested that more aggressive counseling of these men is warranted. On the basis of our data, we recommend that patients with varicoceles be counseled regarding the increased risk of a similar lesion in their male relatives. This is particularly true of brothers, who appear to have the greatest probability of also having a varicocele. Men with undiagnosed varicoceles are at risk of impaired spermatogenesis and steroidogenesis, which may contribute to future infertility and premature androgen deficiency.

CONCLUSIONS

On the basis of the known estimates of the incidence of varicoceles in the general population, as well as the comparison with our control group, a significant increase in varicocele prevalence is present in the first-degree relatives (particularly brothers) of men with known varicoceles. Neither varicocele size nor bilaterality appeared to increase the risk of inheritance. Given the detrimental effect of varicoceles on spermatogenesis and steroidogenesis, patients should be counseled about this increased risk in male family members.

ACKNOWLEDGMENT. To Paul Christos, M.S., M.P.H., Department of Biostatistics and Epidemiology, Weill-Cornell University Medical Center, who provided assistance with the statistical analysis for this manuscript.

REFERENCES

1. Gorelick JI, and Goldstein M: Loss of fertility in men with a varicocele. *Fertil Steril* 59: 613–616, 1993.
2. Witt MA, and Lipshultz LI: Varicocele: a progressive or static lesion? *Urology* 42: 541–543, 1993.
3. Wishahi MM: Detailed anatomy of the internal spermatic vein and the ovarian vein: human cadaver study and operative spermatic venography—clinical aspects. *J Urol* 145: 780–784, 1991.
4. Beinart C, Sniderman KW, Tamura S, *et al*: Left renal vein to inferior vena cava pressure relationships in humans. *J Urol* 127: 1070–1071, 1982.
5. Harrison RM, Lewis RW, and Robert JA: Pathophysiology of varicocele in nonhuman primates: long-term seminal and testicular changes. *Fertil Steril* 46: 500–510, 1986.
6. Lipshultz LI, and Corriere JN Jr: Progressive testicular atrophy in the varicocele patient. *J Urol* 117: 175–177, 1977.
7. Zornio AW, and MacLeod J: Studies in temperature, human semen quality, and varicocele. *Fertil Steril* 24: 854–863, 1973.

8. Goldstein M, and Eid JF: Elevation of intratesticular and scrotal skin surface temperature in men with a varicocele. *J Urol* **142**: 743–745, 1989.
9. MacLeod J: Seminal cytology in the presence of varicocele. *Fertil Steril* **16**: 735–757, 1965.
10. Johnson DE, Pohl DR, and Rivera-Correa H: Varicocele: an innocuous condition? *South Med J* **63**: 34–36, 1970.
11. Kass EJ, and Belman AB: Reversal of testicular growth failure by varicocele ligation. *J Urol* **137**: 475–476, 1987.
12. Steckel J, Dicker AP, and Goldstein M: Relationship between varicocele size and response to varicocelectomy. *J Urol* **149**: 769–771, 1993.
13. Su LM, Goldstein M, and Schlegel PN: The effect of varicocelectomy on serum testosterone levels in infertile men with varicoceles. *J Urol* **154**: 1752–1757, 1995.
14. Goldstein M, Gilbert BR, Dicker AP, *et al*: Microsurgical inguinal varicocelectomy with delivery of the testis: an artery and lymphatic sparing technique. *J Urol* **148**: 1808–1811, 1992.
15. Scott LS, and Young D: Varicocele: a study of its effects on human spermatogenesis, and of the results produced by spermatic vein ligation. *Fertil Steril* **13**: 325–334, 1962.
16. Dubin L, and Amelar RD: Varicocelectomy: 986 cases in a twelve-year study. *Urology* **10**: 446–449, 1977.

COMPARISON OF BILATERAL VERSUS UNILATERAL VARICOCELECTOMY IN MEN WITH PALPABLE BILATERAL VARICOCELES

DOUGLAS SCHERR AND MARC GOLDSTEIN*

From the Department of Urology, New York Hospital-Cornell Medical Center, Center For Male Reproductive Medicine and Microsurgery, James Buchanan Brady Foundation, New York, New York

ABSTRACT

Purpose: The left varicocele is usually larger in men with bilateral varicoceles. We hypothesized that most of the benefit of varicocelectomy would derive from repair of the larger varicocele. To test this hypothesis we prospectively compared the effect of unilateral versus bilateral microsurgical varicocelectomy in men with large (grade III) or moderate (II) left varicocele associated with small but palpable (I) right varicocele.

Materials and Methods: A total of 91 patients were prospectively followed and included in the study. Of the patients 65 underwent bilateral and 26 underwent unilateral left repair. All patients underwent preoperative and postoperative semen analysis.

Results: Motile sperm concentration increased from 12.1 ± 1.7 to 23.7 ± 31.8 (95.8% change) in the bilateral group compared with an increase from 19.5 ± 21.4 to 27.8 ± 34.8 (42.6% change) in the unilateral group ($p < 0.05$). Similarly, sperm concentration increased from 23.8 ± 29.5 to 48.6 ± 61.3 (157.6% change) in the bilateral group compared with an increase from 41.1 ± 40.9 to 59.5 ± 66.7 (44.8% change) in the unilateral group ($p < 0.05$).

Conclusions: Bilateral varicocelectomy resulted in significantly greater improvement in postoperative seminal parameters than unilateral repair in patients with grades II to III left varicocele associated with grade I right varicocele. Even a small, unrepaired palpable right varicocele continues to have a detrimental effect on bilateral testis function. Men with bilateral palpable varicoceles require bilateral repair.

KEY WORDS: varicocele, microsurgery, semen, infertility

The association between male subfertility and varicoceles has been known for the last century.¹ In addition, the association between the presence of a varicocele and a decline in semen parameters with time has been documented.^{2,3} Recently the microscopic surgical anatomy of varicoceles,^{4,5} and microsurgical artery and lymphatic sparing techniques have been described.⁶⁻⁸ The reported incidence of varicocele in the general and subfertile populations is influenced by the method of examination. In the general population the incidence is between 15 and 18% on physical examination,⁹ and 18 and 35% on scrotal sonography and color flow Doppler imaging, respectively.¹⁰

Improvement in semen parameters has been significant following varicocelectomy and related to varicocele size.¹¹⁻¹³ Men with large varicoceles have poorer preoperative semen quality but demonstrate greater postoperative improvement than those with small or medium varicoceles.^{12,13} The consensus is that bilateral surgical repair is indicated for bilateral large varicoceles.¹⁴ The ability of high resolution ultrasound to detect even smaller, subclinical varicoceles led to studies of the benefit of the repair. Although some believe that benefit is derived from repairing such a varicocele,¹⁵ more recent evidence suggests that it does not result in statistically significant improvement in semen parameters.¹³ When 1 side is palpable and the other is subclinical the question becomes whether to repair both sides.

In 1 study 70% of patients with unilateral varicocele on examination had bilateral varicoceles on sonography.¹⁶ Subsequent right varicocelectomy resulted in further improve-

ment in semen analysis in 56% of infertile men who had previously undergone left varicocelectomy and had a missed palpable right varicocele.¹⁷ In patients with bilateral palpable varicoceles, consisting of a large to moderate left varicocele with a small right varicocele, it is uncertain how much additional benefit derives from repairing the right varicocele. Of 65 patients with bilateral varicoceles who met the aforementioned criteria, there was no statistical difference between unilateral and bilateral varicocele ligation.⁸ However, Doppler flow sonography was used to grade varicocele size and a grade I varicocele was, in fact, a subclinical varicocele by physical examination criteria. In this case a statistically significant improvement in semen parameters may not be expected. We hypothesized that most of the benefit of varicocelectomy would derive from repair of the larger, left varicocele. To test this hypothesis we prospectively compared the effect of unilateral versus bilateral microsurgical varicocelectomy in men with large (grade III) or moderate (II) left varicocele associated with small but palpable (I) right varicocele.

MATERIALS AND METHODS

Between 1986 to 1996, 912 men underwent microsurgical varicocelectomy by the same surgeon. Of these men 91 had a moderate (grade II) or large (III) left varicocele associated with a small but palpable (I) right varicocele, and met criteria for inclusion in the study. All patients with azoospermia, those without postoperative semen analysis and those lost to followup were excluded from the study. Preoperatively all patients were told that benefits of unilateral versus bilateral varicocelectomy were uncertain. Of the 91 patients who met

Accepted for publication February 26, 1999.

* Requests for reprints: Department of Urology, Center For Male Reproductive Medicine and Microsurgery, James Buchanan Brady Foundation, 525 E. 68th St., F9W, New York, New York 10021.

inclusion criteria 65 elected to undergo bilateral and 26 opted for only left varicocelectomy.

All 91 patients presented for infertility evaluation. Semen analysis was performed preoperatively and no sooner than 3 months postoperatively. Semen was collected by masturbation after a 3-day abstinence period.¹² All specimens were analyzed within 1 hour of collection. Semen analysis included volume of ejaculate, sperm concentration (million sperm per ml.), percent motility, grade of motility and percent morphologically normal sperm. A Makler† chamber was used to assess sperm concentration. If azoospermia was detected on initial examination, the specimen was centrifuged down to a pellet and reexamined (2 bilateral group patients). Patients with persistent azoospermia on a pellet examination were excluded from study. Video micrography was used to analyze sperm motility. Motility was graded 0—none, 1—poor, 2—fair, 3—good and 4—excellent. A Papanicolaou stain was used to evaluate sperm morphology. The comparison of preoperative and postoperative semen analysis was based on mean values for each semen parameter for a particular patient. Mean plus or minus standard error of preoperative semen analyses was 2 ± 0.1 with a range of 1 to 8. Mean plus or minus standard error of postoperative semen analyses was also 2 ± 0.2 with a range of 1 to 9.

Varicoceles were graded by physical examination in a warm room with the patient standing. Sonography was not used for diagnosis. Varicoceles were graded according to guidelines of the World Health Organization.¹⁸ A grade I varicocele was defined as an impulse with Valsalva's maneuver but not venous tortuosity and a venous diameter less than 1 cm., grade II as a palpable tortuosity through the skin with impulse on Valsalva's maneuver during examination, and grade III as palpable without Valsalva's maneuver and was observed as the classic "bag of worms" appearance through the scrotal skin.

The same surgeon performed all varicocelectomies using a microsurgical technique previously described.⁹ Briefly, a 2 to 3 cm. incision is made over the external inguinal ring. The testicle is delivered into the operative field, and all external and gubernacular veins are ligated. Using the operating microscope at 6X to 25X magnifications, the internal spermatic artery and lymphatics are identified and preserved. All external and internal spermatic veins are clipped or ligated and divided. The vas deferens and its vessels are preserved.

Statistical analysis of the data was performed using the Student t test, which was considered significant at $p < 0.05$. In addition, the preoperative data for each group were compared using linear regression scales. Statistically significant r values were assigned for $p < 0.05$.

RESULTS

Of 91 patients 65 (71.5%) underwent bilateral and 26 (28.5%) underwent unilateral left repair. Mean age, which was not significantly different within the 2 groups, was 35.25 years (range 23 to 54) for the bilateral group, 34.12 (range 21 to 45) for the unilateral group and 35 (range 21 to 54) for the entire population. Varicocele grades were statistically similar between the groups preoperatively. Of the left varicoceles 53% were grade III in the bilateral and 61% were grade III in the unilateral group, and 47% were grade II in the bilateral and 39% were grade II in the unilateral group. Mean left testis volume was 16 cc and mean right testis volume was 18 cc for both groups. Mean followup for postoperative semen analyses was 8 months (range 3 to 24).

Mean sperm concentration increased from 23.86 ± 29.52 million sperm per ml. preoperatively to 48.6 ± 61.3 postoperatively in the bilateral ($p = 0.00016$) and from 41.1 ± 40.9 to 59.5 ± 66.7 in the unilateral ($p = 0.052$) group. Mean total sperm count increased from 69.64 ± 90.08 million sperm

preoperatively to 136.9 ± 157.2 postoperatively in the bilateral ($p = 0.00003$) and from 98.5 ± 94.8 to 167.6 ± 200.3 in the unilateral ($p = 0.052$) group. Percent motile sperm increased from $29.3 \pm 28.5\%$ to $39.5 \pm 19.2\%$ in the bilateral ($p = 0.11$), and from $35.7 \pm 21\%$ to $47.0 \pm 14.2\%$ in the unilateral ($p = 0.03$) group. Percent normal sperm increased from 23.9 ± 24.7 to 30.8 ± 24.5 in the bilateral ($p = 0.31$) and from 36.2 ± 23.1 to 36.3 ± 20.6 in the unilateral ($p = 0.43$) group. Finally, the concentration of motile sperm increased from 12.1 ± 17.7 to 23.7 ± 31.8 in the bilateral ($p < 0.0001$) and from 19.5 ± 21.4 to 27.8 ± 34.8 in the unilateral ($p = 0.07$) group. The effect of varicocele ligation within each group was evaluated using the Student t test (table 1 and figure)

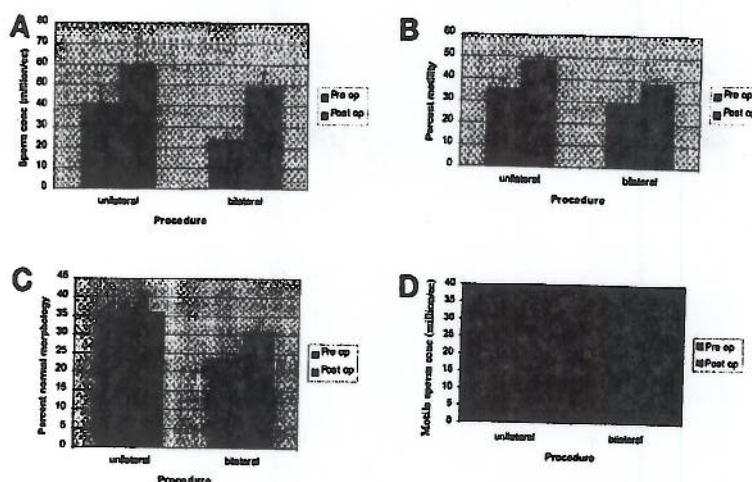
Mean percent change after varicocele ligation in individual semen parameters was compared between groups. A mean plus or minus standard deviation percent change in sperm concentration of 0.73 ± 1.84 was demonstrated in the unilateral ($p < 0.05$) versus 23.78 ± 165.59 in the bilateral ($p < 0.05$) group. Mean percent change in motile sperm concentration (percent motile sperm multiplied by the sperm concentration) was 1.13 ± 2.40 for the unilateral ($p < 0.05$) versus $166.95 \pm 1,135$ for the bilateral ($p < 0.05$) group. Mean percent change for total sperm count was 23.63 ± 161.05 for the bilateral and 0.99 ± 1.91 for the unilateral group. In terms of percent motility, mean percent change for the bilateral and unilateral group was 17.14 ± 69.25 and 0.44 ± 1.27 , respectively. Mean percent change in grade of motility was 0.98 ± 2.91 for bilateral and 0.17 ± 0.51 for unilateral repair. Mean percent change in percent normal sperm was 23.61 ± 79.14 for the bilateral and 0.29 ± 1.00 for the unilateral group. Although all semen parameters revealed greater mean percent changes in the bilateral group, sperm concentration, count and motile sperm concentration achieved a statistically significant larger mean percent change in the bilateral versus unilateral group. Interestingly, the degree of change seen in each index was significantly greater for the bilateral group (table 2).

It was necessary to determine whether the preoperative differences in semen parameters between the groups had an impact on postoperative improvement for valid comparison between the 2 groups of data. Linear regression scales were developed for each preoperative semen parameter and compared with the postoperative percent change for that parameter. Due to complex statistical considerations the improvement seen in morphology (percent normal sperm) of the bilateral versus unilateral group may not be valid since the preoperative values between the groups differed for these 2 parameters. Nonetheless, morphology improved to a greater degree after bilateral varicocelectomy. However, all other semen parameters are statistically valid points of comparison between the 2 groups.

TABLE 1. Mean pretreatment and posttreatment semen parameters

	Mean \pm SE		p Value
	Preop.	Postop.	
Bilat. group:			
Concentration	23.8 \pm 29.5	48.6 \pm 61.3	0.00016
Count	69.6 \pm 90.0	136.9 \pm 157.2	0.00003
% Motility	29.3 \pm 28.5	39.5 \pm 19.2	0.03
% Normal	23.9 \pm 24.7	30.8 \pm 24.5	0.31
Motile sperm concentration	12.1 \pm 17.7	23.7 \pm 31.8	0.000046
Unilat. group:			
Concentration	41.1 \pm 40.9	59.5 \pm 66.7	0.0515
Count	98.5 \pm 94.8	167.6 \pm 200.3	0.0519
% Motile	35.7 \pm 21.0	47.0 \pm 14.2	0.1115
% Normal	36.2 \pm 23.1	36.3 \pm 20.3	0.4342
Motile sperm concentration	19.5 \pm 21.4	27.8 \pm 34.8	0.0670

† Sefi Medical Industries, Ltd., Haifa, Israel.



A, changes in sperm concentration. B, changes in sperm motility. C, changes in sperm morphology. D, motile sperm concentration

TABLE 2. Mean percent change

	Mean \pm SD		p Value
	Unilat. Group	Bilat. Group	
Sperm concentration	0.73 \pm 1.84	23.78 \pm 165.59	0.04
Total sperm count	0.99 \pm 1.91	23.63 \pm 161.05	0.01
% Motility	0.44 \pm 1.27	17.14 \pm 69.25	0.22
Grade motility	0.17 \pm 0.51	0.98 \pm 2.91	0.55
% Normal sperm	0.29 \pm 1.00	23.61 \pm 79.14	0.05
Motile sperm concentration	1.13 \pm 2.40	166.95 \pm 1135	0.02

DISCUSSION

Recent studies suggest that response to varicocele surgery is related to varicocele size, with greater improvement in semen parameters resulting from the repair of larger versus small varicoceles.^{12,13} The significance of sonographically detected, or subclinical, varicoceles is controversial.^{13,15,16} Current reports suggest that repair of subclinical varicoceles does not seem to improve semen parameters significantly.¹⁹ Varicoceles detected by physical examination are associated with a greater postoperative improvement in semen parameters than those detected sonographically.²⁰ Varicoceles detected by a thorough physical examination are more predictive of a good clinical outcome than venous diameter on ultrasound.²¹ However, an important controversy that remains is whether a small but clinically palpable right varicocele associated with a large or moderate left varicocele should be repaired.

There has been no consensus in the infertility literature as to the management of bilateral varicoceles, especially when 1 side is a grade I varicocele. Grasso et al have argued that due to the potential added morbidity and additional operating time the benefit obtained from repairing a small, right varicocele associated with a large left varicocele is minimal.⁸ However, they categorized cases according to sonographic criteria rather than by physical examination. As Jarow et al indicated, varicoceles detected solely by sonography are different from those detected by physical examination in terms of the impact on postoperative seminal improvement.¹³ There is greater potential for an improvement in sperm motility, concentration and morphology when varicocelectomy is performed on clinically palpable varicoceles.¹³ Additionally, Grasso et al performed retroperitoneal varicocele ligation using the Palomo technique rather than microsurgical artery sparing varicocelectomy.⁸ There is a statistically significant decrease in postoperative hydrocele formation and iatrogenic spermatic artery injury using the microsurgical technique of varicocelectomy compared to nonmicrosurgical techniques.^{6,22}

Our data suggest that maximal improvement in semen parameters is achieved by a bilateral repair in patients with a grade I, palpable right varicocele associated with a grade II to III left varicocele. The postoperative changes in semen parameters consistently demonstrated more significant improvement in our bilateral group. Varicocele ligation has already been shown to improve postoperative semen parameters in the subfertile population.^{6,23-25} There was a statistically significant improvement postoperatively for every semen parameter in the bilateral group. However, in the unilateral group statistical significance was not quite achieved but was only approached for the improvements in sperm concentration and count, and just barely in motility. Since all surgery in this population was performed using the same procedure and by the same operating surgeon, technical differences cannot explain the significance of these findings. The failure of all semen parameters to improve significantly after unilateral repair while statistically significant improvement was seen after bilateral repair should not discount the unilateral repair but should underscore the importance of a small right varicocele. In addition, it suggests that there is a bilateral effect of unilateral varicocele. In conclusion, a palpable right varicocele associated with a large or moderate left varicocele should be repaired for maximal improvement in semen parameters.

REFERENCES

- Zorgniotti, A. W.: The spermatozoa count: a short history. *Urology*, 5: 673, 1975.
- Gorelick, J. I. and Goldstein, M.: Loss of fertility in men with a varicocele. *Fertil. Steril.*, 59: 613, 1993.
- Chehval, M. J. and Purcell, M. H.: Determination of semen parameters over time in men with untreated varicoceles: evidence of progressive testicular damage. *Fertil. Steril.*, 57: 174, 1992.
- Beck, E., Schlegel, P. N. and Goldstein, M.: Intraoperative varicocele anatomy: a macroscopic and microscopic study. *J. Urol.*, 148: 1190, 1992.
- Turner, T., Caplis, L. A. and Brown, K. J.: Vascular anatomy of experimentally induced left varicocele in the rat. *Lab. Animal Sci.*, 46: 206, 1996.
- Goldstein, M., Gilbert, B. R., Dicker, A. P., Dwosh, J. and Gnecco, C.: Microsurgical inguinal varicocelectomy with delivery of the testis: an artery and lymphatic sparing technique. *J. Urol.*, 148: 1808, 1992.
- Marmar, J. L. and Kim, Y.: Subinguinal microsurgical varicocelectomy: a technical critique and statistical analysis of semen and pregnancy data. *J. Urol.*, 152: 1127, 1994.
- Grasso, M., Lania, C., Castelli, M., Galli, L. and Rigatti, P.:

- Bilateral varicocele: impact of right spermatic vein ligation on fertility. *J. Urol.*, 153: 1847, 1995.
9. Jarow, J. P., Coburn, M. and Sigman, M.: Incidence of varicoceles in men with primary and secondary infertility. *Urology*, 47: 73, 1996.
 10. Meacham, R. B., Townsend, R. R., Rademacher, E. and Drose, J. A.: The incidence of varicoceles in the general population when evaluated by physical exam, Gray scale sonography and color Doppler sonography. *J. Urol.*, 151: 1535, 1994.
 11. Charney, C. W.: Effect of varicoceles on fertility: results of varicocelectomy. *Fertil. Steril.*, 13: 47, 1962.
 12. Steckel, J., Dicker, A. P. and Goldstein, M.: Relationship between varicocele size and response to varicocelectomy. *J. Urol.*, 149: 769, 1993.
 13. Jarow, J. P., Ogle, S. R. and Eskew, L. A.: Seminal improvement following repair of ultrasound detected subclinical varicoceles. *J. Urol.*, 155: 1287, 1996.
 14. Hadziselimovic, F., Herzog, B. and Jenny, P.: The chance of fertility in boys after corrective surgery for varicocele. *J. Urol.*, part 2, 154: 731, 1995.
 15. Dhabuwala, B., Hamid, S. and Moghissi, K. S.: Clinical versus subclinical varicocele: improvement in fertility after varicocelectomy. *Fertil. Steril.*, 57: 854, 1992.
 16. McClure, F. D. and Hricak, H.: Scrotal ultrasound in the infertile male: detection of subclinical unilateral and bilateral varicoceles. *J. Urol.*, 135: 711, 1986.
 17. Amelar, R. D. and Dubin, L.: Right varicocelectomy in selected infertile patients who have failed to improve after previous left varicocelectomy. *Fertil. Steril.*, 47: 833, 1987.
 18. World Health Organization: Comparison among different methods for the diagnosis of varicocele. *Fertil. Steril.*, 43: 575, 1985.
 19. Howards, S. S.: Subclinical varicocele. *Fertil. Steril.*, 57: 725, 1992.
 20. Marks, J. L., McMahon, R. and Lipschultz, L. I.: Predictive parameters of successful varicocele repair. *J. Urol.*, 136: 609, 1986.
 21. Eskew, L. A., Watson, N. E., Wolfman, N., Bechtold, R., Scharling, E. and Jarow, J. P.: Ultrasonographic diagnosis of varicoceles. *Fertil. Steril.*, 60: 693, 1993.
 22. Sayfan, J., Soffer, Y. and Orda, R.: Varicocele treatment: prospective randomized trial of three methods. *J. Urol.*, 148: 1447, 1992.
 23. Nilsson, S., Edvinsson, A. and Nilsson, B.: Improvement of semen and pregnancy rate after ligation and division of the internal spermatic vein: fact or fiction? *Brit. J. Urol.*, 51: 591, 1979.
 24. Vermeulen, A. and Vandeghe, M.: Improved fertility after varicocele correction: fact or fiction? *Fertil. Steril.*, 42: 249, 1984.
 25. Laven, J. S., Haans, L. C., Mali, W. B., te Velde, E. R., Wensing, C. J. and Eimers, J. M.: Effects of varicocele treatment in adolescents: a randomized study. *Fertil. Steril.*, 58: 756, 1992.

MICROSURGICAL INGUINAL VARICOCELECTOMY WITH DELIVERY OF THE TESTIS: AN ARTERY AND LYMPHATIC SPARING TECHNIQUE

MARC GOLDSTEIN,* BRUCE R. GILBERT, ADAM P. DICKER, JACK DWOSH AND CLAIRE GNECCO

From the Department of Surgery, Division of Urology, The James Buchanan Brady Foundation, The New York Hospital-Cornell Medical Center and The Population Council Center for Biomedical Research, New York, New York

ABSTRACT

Conventional techniques of varicocele repair are associated with substantial risks of hydrocele formation, ligation of the testicular artery, and varicocele recurrence. We describe a microsurgical technique of varicocelectomy that significantly lowers the incidence of these complications. The testicle is delivered through a 2 to 3 cm. inguinal incision, and all external spermatic and gubernacular veins are ligated. The testis is returned to the scrotum and the spermatic cord is dissected under the operating microscope. The testicular artery and lymphatics are identified and preserved. All internal spermatic veins are doubly ligated with small hemoclips or 4-zero silk and divided. The vas deferens and its vessels are preserved.

Initially, we performed 33 conventional inguinal varicocelectomies in 24 men without delivery of the testis or use of a microscope. Postoperatively, 3 unilateral hydroceles (9%) and 3 unilateral recurrences (9%) were detected. For the next 12 cases 2.5× loupes were used resulting in no hydroceles but another recurrence (8%). We then performed 640 varicocelectomies in 429 men using the microsurgical technique with delivery of the testis. Among 382 men available for followup examination from 6 months to 7 years postoperatively no hydroceles and no cases of testicular atrophy were found. A total of 4 unilateral recurrent varicoceles (0.6%) was identified. The differences between the techniques in the incidence of hydrocele formation and varicocele recurrence are highly significant ($p < 0.001$). No wound infections occurred in any men. Four scrotal hematomas (0.6%), 1 of which required surgical drainage, occurred in the group with microsurgical ligation and delivery of the testis compared to none with the conventional technique. Preoperative and postoperative semen analyses (mean 3.57 analyses per patient) were obtained on 271 men. The changes in sperm count $\times 10^6$ cc (36.9 to 46.8, $p < 0.001$), per cent motility (39.6 to 45.7%, $p < 0.001$) and per cent normal forms (48.4 to 52.10%, $p < 0.001$) were highly significant. The pregnancy rate was 152 of 357 couples (43%) followed for a minimum of 6 months postoperatively.

Delivery of the testis through a small inguinal incision provides direct visual access to all possible avenues of testicular venous drainage. The operating microscope allows identification of the testicular artery, lymphatics and small venous channels. This minimally invasive, outpatient technique results in a significant decrease in the incidence of hydrocele formation, testicular artery injury and varicocele recurrence.

KEY WORDS: testis, varicocele, microsurgery

Varicocele is found in approximately 15% of the general population but in at least 35% of infertile men.¹ Traditional approaches to the surgical repair of varicocele include retroperitoneal² and inguinal^{3,4} operations. Hydrocele is the most common complication of these operations. Szabo and Kessler reviewed the incidence of hydrocele formation after varicocelectomy and found rates varying from 3 to 39%, and in their own series an incidence of 7.2%.⁵ Analysis of the protein concentration of the hydrocele fluid indicated that lymphatic obstruction is the cause of hydrocele formation after varicocelectomy.⁶

Testicular atrophy or azoospermia is the most devastating complication of varicocelectomy but this is rarely reported and the incidence, therefore, is unknown. Animal⁸ and human⁷ studies suggest that ligation of the testicular artery is associated with a substantial risk of testicular injury.

The incidence of persistent or recurrent varicocele following surgical repair in adults varies from 5 to 45%⁹⁻¹¹ and appears to be even more common after repair of the pediatric varico-

cele.¹²⁻¹⁴ Venography of recurrent varicocele has revealed that most recurrences are the result of mid retroperitoneal or low inguinal parallel collaterals^{13,15,16} but 7% of all recurrences appear to be due to scrotal collaterals.¹⁷

Attempts at decreasing the complication and recurrence rates following varicocelectomy led to microsurgical approaches.¹⁸⁻²⁰ These methods have the advantages of identification and preservation of the testicular artery and lymphatics, and decrease the incidence of hydrocele formation and testicular artery injury. These approaches do not address retroperitoneal, parallel inguinal or scrotal collaterals, which are the most common causes of recurrent varicocele. Intraoperative venography performed at the time of conventional varicocelectomy^{13,21} or balloon occlusion^{15,22,23} often visualizes these collaterals but substantially increases the operating time and still results in a significant incidence of varicocele recurrence.^{17,24-26} We describe the evolution of a microsurgical approach with delivery of the testis, which decreases the complication and recurrence rates after varicocelectomy.

MATERIALS AND METHODS

Patients. A total of 429 men and boys 12 to 54 years old with varicoceles underwent 640 varicocelectomies (211 bilateral). Of

Accepted for publication May 29, 1992.

* Requests for reprints: Division of Urology, The New York Hospital-Cornell Medical Center, 525 E. 68th St., New York, New York 10021.

the men 368 presented with infertility at least 1 year in duration. In the remainder the indication for surgery was pain or testicular atrophy. Examination for varicocele was performed in a warm room with the patient in the upright position with the aid of a Valsalva maneuver and was confirmed by 2 independent physicians. Men and boys with suspected subclinical varicoceles were excluded. Men who presented with infertility had at least 2 semen analyses obtained preoperatively after 3 days of abstinence and at least 1 month apart. The men were examined at 1, 3 and 6 months, and 1 year postoperatively. Semen analyses were obtained at 3 and 6 months, and 1 year postoperatively. Scrotal transillumination was performed at each postoperative visit for the detection of hydrocele. Initially, 33 varicocelectomies were performed with a standard inguinal approach without magnification. Inability to visualize and preserve reliably the testicular artery and lymphatics led to the use of 2.5 \times magnification loupes for the next 12 operations. Although this method improved our ability to identify the testicular artery to at least two-thirds of the cases, recurrent varicoceles led to dissatisfaction with this operation and to the development of the procedure described. Because of the danger of testicular artery injury with blind cord block,²⁷ general or regional anesthesia was used in all patients.

Surgical technique. The location of the external inguinal ring is marked on the skin. An incision is made beginning at the external inguinal ring and extended 2.0 to 3 cm. laterally in the skin crease (fig. 1). The incision is deepened through Camper's fascia. With small Richardson retractors the superficial epigastric artery and vein, and surrounding fat are retracted. Scarpa's fascia is retracted revealing the external oblique aponeurosis, which is opened the length of the incision in the direction of its fibers through the external inguinal ring. A 3-zero polyglactin suture placed at the apex of the incision in the external oblique aponeurosis facilitates later closure. In men with prior inguinal surgery or a high external ring the external oblique aponeurosis is not opened and the spermatic cord is grasped just below the external ring. The spermatic cord is then encircled with a Babcock clamp and delivered through the wound. The ileoinguinal and genital branches of the genitofemoral nerves are excluded from the spermatic cord, which is surrounded with a large Penrose drain. The spermatic cord is then bluntly dissected with a finger down to the scrotum and the testis is delivered through the wound.

All external spermatic veins are identified and doubly ligated with hemoclips or 4-zero silk and divided (fig. 1). The gubernaculum is inspected for the presence of veins exiting from the tunica vaginalis. These are either cauterized, doubly ligated or

clipped and divided. The testis is then returned to the scrotum and a tongue blade covered with a Penrose drain is placed beneath the cord structures. The operating microscope is then brought into the field. Under 8 \times magnification the external and internal spermatic fascias are opened. A 1% papaverine solution is sprinkled on the spermatic cord, which is inspected for the presence of pulsations revealing the location of the testicular artery. If the testicular artery is identified it is dissected free of all surrounding tissue, tiny veins and lymphatics, using a fine tipped nonlocking microsurgical needle holder and smooth small forceps. The artery is encircled with a 1-zero silk suture for positive identification (fig. 2, A). If pulsations of the suspected artery are not obvious, a partial occlusion test may be performed by elevating the artery with the tips of the needle holder until it is completely occluded and then slowly lowering it until a pulsating column of blood appears just over the needle holder. If the artery is not immediately identified the spermatic cord is carefully dissected beginning with the largest vein. The veins are stripped clean of adherent lymphatics and the underside of the largest veins are inspected for an adherent artery. In approximately 50% of the cases the testicular artery is adherent to the underside of a large vein. All veins within the spermatic cord, with the exception of the vasal veins, are doubly ligated with either hemoclips or by passing 2, 4-zero silk sutures, 1 black and 1 white, beneath the vein (fig. 2, B). These sutures are then tied and the vein is divided. If the vas deferens is accompanied by dilated veins greater than 3 mm. in diameter, they are dissected free of the vasal artery and ligated. The vas deferens is always accompanied by 2 sets of vessels. As long as at least 1 set of vasal veins remains intact venous congestion will not occur.

At the completion of the dissection the spermatic cord is run over the index finger and inspected to make sure all veins have been identified and ligated. Small veins adherent to the testicular artery are dissected free and ligated if greater than 1 mm. or cauterized using a bipolar unit with a jeweler's forcep tip. At the completion of the dissection only the testicular artery, lymphatics (fig. 3), and vas deferens and its vessels remain. The testis is then delivered again, inspected for bleeders and returned to the scrotum. The external oblique aponeurosis is reapproximated with continuous suture of the previously placed 3-zero polyglactin. Scarpa's fascia and Camper's fascia are reapproximated with a single continuous 3-zero plain catgut suture and the skin is approximated with sterile strips. A scrotal support is stuffed with fluff type dressings. The patient is discharged on the same day as the operation with a prescription for acetaminophen with codeine. Light work may be resumed within 2 or 3 days. Statistical analysis of semen data was performed using the paired Wilcoxon signed rank test.²⁸ Differences in the incidence of complications were compared with a Z test.²⁹

RESULTS

Among 33 varicocelectomies performed without benefit of the microscope and without delivery of the testis 3 recurrent varicoceles (9%) and 3 hydroceles (9%) were detected 6 months or more postoperatively. Neither atrophy nor azoospermia was detected on followup examination in any of these men. No hematomas or wound infections occurred. In the next 12 men 2.5 \times loupe magnification was used without delivery of the testis. The testicular artery and lymphatics could be identified in two-thirds of these patients. No hydroceles and 1 recurrent varicocele (8%) were identified. A total of 429 men underwent 640 microsurgical varicocelectomies with delivery of the testis as described. Of these men 382 were examined at least 6 months postoperatively. No hydroceles and 4 recurrences were detected (0.6%).

A total of 4 hematomas occurred (0.6%): 1 required surgical drainage and 3 resolved spontaneously. No incidence of atrophy

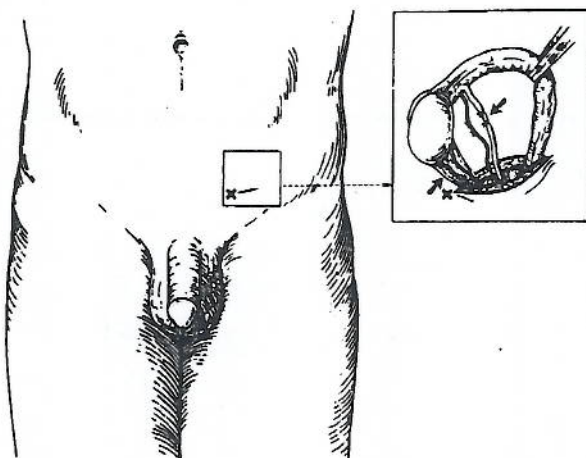


FIG. 1. X marks site of external inguinal ring. Incision is 2.5 to 3 cm. long. Inset: after delivery of testis, external spermatic and gubernacular veins are doubly ligated with 4-zero silk and divided.

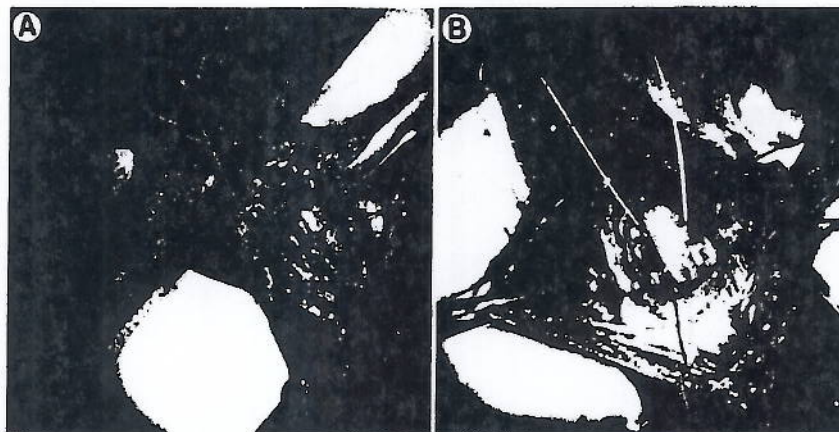


FIG. 2. A, testicular artery is identified and tagged with 1-zero silk suture. B, internal spermatic veins are cleaned and double 4-zero silk sutures, 1 black and 1 white, are passed beneath them before ligation and division.



FIG. 3. Lymphatics are clearly identified and preserved

Mean preoperative and postoperative semen analysis results in 271 men

	Preop.	Postop.	Mean Difference ± SE	P Value
Sperm concentration × 10 ⁶ /cc	36.97	46.85	10.63 ± 2.33	<0.001
% Motility	39.62	45.66	5.88 ± 1.20	<0.001
% Normal forms	48.42	52.10	3.17 ± 1.29	<0.001
% Tapered forms	8.84	4.11	4.75 ± 0.69	<0.001

or azoospermia was identified. There were no wound infections. Although no systemic antibiotics were used, 1% neomycin irrigation was used from the moment the incision was made and every few minutes until completion of the operation. The average operating time for the first 20 cases performed microsurgically was 78 minutes. Subsequently, the operating time has decreased to between 25 and 40 minutes per side. Preoperative and postoperative semen analyses were obtained on 271 men followed at least 3 months postoperatively. A mean of 3.57 analyses was obtained per patient. Improvements in sperm count, motility, normal forms and decreased percentage of tapered forms are statistically significant (see table). The pregnancy rate among couples who were followed for a minimum of 6 months postoperatively was 43% (152 of 357).

DISCUSSION

Our microsurgical technique clearly decreases the incidence of hydrocele and recurrent varicocele. Hydroceles can sometimes grow to a large size and require a secondary operation. Although the effect of hydrocele on fertility is unknown, it is possible that a large hydrocele may alter the temperature regulating mechanism of the testis and have an adverse influence on fertility. Microsurgical technique allows for clear identification and preservation of lymphatics, and avoidance of this complication.

Testicular atrophy and azoospermia following varicocelectomy are risks associated with ligation of the testicular artery.^{6,30} Preservation of the testicular artery is particularly critical when operating upon a solitary testis, or in children⁷ and adolescents on whom the operation is being performed prophylactically.

Several studies have clearly shown that recurrent varicoceles are usually due to venous collaterals that bypass the inguinal portion of the spermatic cord^{13,15,16} and that 7% of the recurrences are apparently due to scrotal collaterals.¹⁷ Delivery of the testis, and ligation of all external spermatic and gubernacular veins eliminate these collaterals. In addition, during microsurgical dissection of the spermatic cord small veins immediately adjacent to the testicular artery are often identified. If missed, these may slowly enlarge and cause recurrence. Preservation of the vasal veins assures adequate venous return. Even percutaneous balloon occlusion of the internal spermatic veins results in a substantially higher recurrence rate than we have reported with our current technique.^{17,24-26} Furthermore, balloon occlusion is a more lengthy procedure, involves exposure to radiation and may result in complications from perforation of the veins, migration of the coil or balloon, or failure to catheterize the spermatic veins.³¹ The 2 to 3.0 cm. incision we currently use for microsurgical varicocelectomy is no larger than the combined incisions used for laparoscopic varicocelectomy without the risk of intraperitoneal morbidity.

Substantial evidence is accumulating that varicocele causes duration-dependent testicular injury.³²⁻³⁸ Varicocelectomy can prevent further worsening of semen quality. Our microsurgical technique is a safe, minimally invasive, outpatient approach to varicocelectomy that lessens the incidence of hydrocele formation and varicocele recurrence, and assures preservation of the testicular artery.

Scott Schlemmer, Donna Ambramski and Gail Morrison assisted in the collection and analysis of data.

REFERENCES

1. Greenberg, S. H.: Varicocele and male fertility. *Fertil. Steril.*, **28**: 699, 1977.
2. Palomo, A.: Radical cure of varicocele by a new technique: preliminary report. *J. Urol.*, **61**: 604, 1949.
3. Ivanissevich, O.: Left varicocele due to reflux: experience with 4,470 operative cases in forty-two years. *J. Int. Coll. Surg.*, **34**: 742, 1960.
4. Dubin, L. and Amelar, R. D.: Varicocelectomy: 986 cases in a twelve-year study. *Urology*, **10**: 446, 1977.
5. Szabo, R. and Kessler, R.: Hydrocele following internal spermatic vein ligation: a retrospective study and review of the literature. *J. Urol.*, **132**: 924, 1984.
6. MacMahon, R. A., O'Brien, M. C. and Cussen, L. J.: The use of microsurgery in the treatment of the undescended testis. *J. Ped. Surg.*, **11**: 521, 1976.
7. Fowler, R. and Stephens, F. D.: The role of testicular vascular anatomy in the salvage of high, undescended testes. In: *Congenital Malformations of the Rectum, Anus and Genito-Urinary Tracts*. Edited by F. D. Stephens. Edinburgh: Livingstone, p. 306, 1963.
8. Sayfan, J., Adam, Y. G. and Soffer, Y.: A new entity in varicocele subfertility: the "cremasteric reflux." *Fertil. Steril.*, **33**: 88, 1980.
9. Rothman, C. M., Newmark, H., III and Karson, R. A.: The recurrent varicocele—a poorly recognized problem. *Fertil. Steril.*, **35**: 552, 1981.
10. Homonnai, Z. T., Fainman, N., Engelhard, Y., Rudberg, Z., David, M. P. and Paz, G.: Varicocelectomy and male fertility: comparison of semen quality and recurrence of varicocele following varicocelectomy by two techniques. *Int. J. Androl.*, **3**: 447, 1980.
11. Belgrano, E., Puppo, P., Quattrini, S., Trombetta, C. and Giuliani, L.: The role of venography and sclerotherapy in the management of varicocele. *Eur. Urol.*, **10**: 124, 1984.
12. Gorenstein, A., Katz, S. and Schiller, M.: Varicocele in children: "to treat or not to treat"—venographic and manometric studies. *J. Ped. Surg.*, **21**: 1046, 1986.
13. Levitt, S., Gill, B., Katlowitz, N., Kogan, S. J. and Reda, E.: Routine intraoperative post-ligation venography in the treatment of the pediatric varicocele. *J. Urol.*, **137**: 716, 1987.
14. Reitelman, C., Burbige, K. A., Sawczuk, I. S. and Hensle, T. W.: Diagnosis and surgical correction of the pediatric varicocele. *J. Urol.*, **138**: 1038, 1987.
15. Murray, R. R., Jr., Mitchell, S. E., Kadir, S., Kaufman, S. L., Chang, R., Kinnison, M. L., Smyth, J. W. and White, R. I., Jr.: Comparison of recurrent varicocele anatomy following surgery and percutaneous balloon occlusion. *J. Urol.*, **135**: 286, 1986.
16. Sayfan, J., Adam, Y. G. and Soffer, Y.: A natural "venous bypass" causing postoperative recurrence of a varicocele. *J. Androl.*, **2**: 108, 1981.
17. Kaufman, S. L., Kadir, S., Barth, K. H., Smyth, J. W., Walsh, P. C. and White, R. I., Jr.: Mechanisms of recurrent varicocele after balloon occlusion or surgical ligation of the internal spermatic vein. *Radiology*, **147**: 435, 1983.
18. Wosnitzer, M. and Roth, J. A.: Optical magnification and Doppler ultrasound probe for varicocelectomy. *Urology*, **22**: 24, 1983.
19. Marmar, J. L., DeBenedictis, T. J. and Prais, D.: The management of varicoceles by microdissection of the spermatic cord at the external inguinal ring. *Fertil. Steril.*, **43**: 583, 1985.
20. Kaye, K. W.: Modified high varicocelectomy: outpatient microsurgical procedure. *Urology*, **32**: 13, 1988.
21. Zaontz, M. R. and Firlit, C. F.: Use of venography as an aid in varicocelectomy. *J. Urol.*, **138**: 1041, 1987.
22. Lima, S. S., Castro, M. P. and Costa, O. F.: A new method for the treatment of varicocele. *Andrologia*, **10**: 103, 1978.
23. Walsh, P. C. and White, R. I., Jr.: Balloon occlusion of the internal spermatic vein for the treatment of varicoceles. *J.A.M.A.*, **246**: 1701, 1981.
24. Weissbach, L., Thelen, M. and Adolphs, H.-D.: Treatment of idiopathic varicoceles by transfemoral testicular vein occlusion. *J. Urol.*, **126**: 354, 1981.
25. Morag, B., Rubinstein, Z. J., Goldwasser, B., Yerushalmi, A. and Lunnenfeld, B.: Percutaneous venography and occlusion in the management of spermatic varicoceles. *AJR*, **143**: 635, 1984.
26. Porst, H., Bahren, W., Lenz, M. and Altwein, J. E.: Percutaneous sclerotherapy of varicoceles—an alternative to conventional surgical methods. *Brit. J. Urol.*, **56**: 73, 1984.
27. Goldstein, M., Young, G. P. H. and Einer-Jensen, N.: Testicular artery damage due to infiltration with a fine-gauge needle: experimental evidence suggesting that blind spermatic cord block should be abandoned. *Surg. Forum*, **34**: 653, 1983.
28. Wilcoxon, F.: Individual comparisons by ranking methods. *Biometrics*, **1**: 80, 1945.
29. Fleiss, J. L.: *Statistical Methods for Rates and Proportions*, 2nd ed. New York: John Wiley & Sons, 1981.
30. Silber, S. J.: Microsurgical aspects of varicocele. *Fertil. Steril.*, **31**: 230, 1979.
31. White, R. I., Jr., Kaufman, S. L., Barth, K. H., Kadir, S., Smyth, J. W. and Walsh, P. C.: Occlusion of varicoceles with detachable balloons. *Radiology*, **139**: 327, 1981.
32. Harrison, R. M., Lewis, R. W. and Roberts, J. A.: Pathophysiology of varicocele in nonhuman primates: long-term seminal and testicular changes. *Fertil. Steril.*, **46**: 500, 1986.
33. Russell, J. K.: Varicocele, age, and fertility. *Lancet*, **273**: 222, 1957.
34. Lipshultz, L. I. and Corriere, J. N., Jr.: Progressive testicular atrophy in the varicocele patient. *J. Urol.*, **117**: 175, 1977.
35. Nagler, H. M., Li, X.-Z., Lizza, E. F., Deitch, A. and deVere White, R.: Varicocele: temporal considerations. *J. Urol.*, **134**: 411, 1985.
36. Hadziselimović, F., Herzog, B., Liebundgut, B., Jenny, P. and Buser, M.: Testicular and vascular changes in children and adults with varicocele. *J. Urol.*, **142**: 583, 1989.
37. Kass, E. J., Chandra, R. S. and Belman, A. B.: Testicular histology in the adolescent with a varicocele. *Pediatrics*, **79**: 996, 1987.
38. Gorelick, J. and Goldstein, M.: Loss of fertility in men with varicocele. *Fertil. Steril.*, in press.

THE EFFECT OF VARICOCELECTOMY ON SERUM TESTOSTERONE LEVELS IN INFERTILE MEN WITH VARICOCELES

LI-MING SU, MARC GOLDSTEIN AND PETER N. SCHLEGEL

From the Division of Male Reproductive Medicine and Microsurgery, James Buchanan Brady Foundation, Department of Urology, New York Hospital-Cornell Medical Center and Center for Biomedical Research, Population Council, New York, New York

ABSTRACT

Purpose: We evaluated the effect of varicocelectomy on serum testosterone.

Materials and Methods: We retrospectively reviewed the effect of varicocelectomy on serum testosterone levels in 53 infertile men with varicoceles.

Results: Mean serum testosterone increased from a preoperative level of 319 ± 12 to 409 ± 23 ng./dl. postoperatively ($p < 0.0004$). Men with at least 1 firm testis preoperatively had a greater increase in serum testosterone ($p < 0.005$). An inverse correlation was noted between preoperative testosterone levels and change in testosterone after varicocelectomy ($r = -0.34$, $p < 0.013$).

Conclusions: Varicocelectomy can increase serum testosterone for infertile men with varicoceles. Although improvement in serum testosterone does not necessarily cause a direct improvement in semen quality, varicocelectomy may improve hormonal and spermatogenic function.

KEY WORDS: varicocele, testosterone, infertility, testis

In the last 2 decades there has been growing evidence that the pathophysiology of varicoceles may partially involve dysfunction of the hypothalamic-pituitary-gonadal axis. The literature strongly supports the hypothesis that hormonal dysfunction occurs at the level of the Leydig cell. Weiss et al demonstrated the suppression of *in vitro* testosterone synthesis by the testicular tissue of men with varicoceles and severe oligospermia compared to normal men.¹ This apparent disruption of androgen biosynthesis was later supported by Ando et al, who demonstrated an increase in the 17-hydroxyprogesterone-to-testosterone ratio after intramuscular human chorionic gonadotropin stimulation, suggesting enzymatic impairment of the final steps of testosterone biosynthesis in men with varicoceles.² Sirvent et al used histological and immunohistochemical techniques to study testicular biopsies from men with varicoceles and noted a decreased number of Leydig cells staining positive with the testosterone peroxidase-antiperoxidase method.³ Taken together these studies suggest that varicoceles cause a disturbance of Leydig cell function with decreased testosterone biosynthesis. Despite the apparent lower production of testosterone by Leydig cells in men with varicoceles several studies have demonstrated no significant difference in peripheral blood levels of testosterone compared to levels in men without varicoceles.^{1,4,5} It is possible that the decreased testosterone synthesis per Leydig cell is compensated for by an increase in Leydig cell number. This hypothesis is supported by Sirvent et al, who documented Leydig cell hyperplasia in men with varicoceles.³

Although the detrimental effect of varicoceles on Leydig cell function appears well established, the reversibility of the hormonal dysfunction with varicocelectomy remains controversial. Hudson et al have demonstrated at 6 to 12 months after retroperitoneal varicocelectomy that in 14 men with varicoceles and oligospermia there was a trend toward increased serum testosterone, which was not significantly different from the preoperative levels.⁶ Segenriech et al also noted an insignificant rise in serum testosterone in 24 varicocele patients who underwent high ligation of the internal spermatic vein.⁷ On the other hand, Comhaire and Vermeulen evaluated 10 patients with varicoceles and sexual inadequacy (mean testosterone 346.2 ng./dl.) who had low preoperative testosterone levels and noted that plasma testosterone

one concentration returned to normal after surgery.⁸ It is important to remember that serum testosterone levels are highly variable for an individual. Given the inability of limited studies to detect smaller but clinically important changes in serum testosterone larger studies may be needed to provide the statistical power necessary to demonstrate the increase in serum testosterone after varicocelectomy. To clarify the effect of varicocelectomy on serum testosterone levels we retrospectively studied 53 infertile men with varicoceles who underwent microsurgical inguinal varicocelectomy.

MATERIALS AND METHODS

Patients. We retrospectively reviewed the records of 53 patients who underwent varicocelectomy with documented preoperative and postoperative serum testosterone levels. These patients presented to 1 of 2 male infertility specialists at our institution. Duration of infertility ranged from 0 to 156 months (mean 21). Patient age ranged from 22 to 57 years (mean 35). Preoperative evaluation included a complete history, physical examination, at least 2 semen analyses and measurement of serum hormone levels. A total of 52 patients presented because of presumed male factor infertility and 1 had testicular pain ipsilateral to a varicocele. Varicoceles were graded as I to III and recorded as unilateral or bilateral based on physical examination.⁹ The consistency of the testes was firm or soft. Varicocelectomy was performed only on palpable varicoceles using a microsurgical inguinal or subinguinal technique.¹⁰ Semen analyses were obtained at 3-month intervals postoperatively. Those who had undergone previous surgical interventions (for example orchiopexy) or were concurrently receiving medical treatment (for example clomiphene citrate) were excluded from the study.

Semen analysis. Semen specimens were obtained by masturbation after a minimum of 3 days of abstinence. The samples were examined within 1 hour of collection and semen parameters, including sperm concentration, semen volume, percent motility of sperm and sperm morphology, were assessed according to criteria defined by the World Health Organization.¹¹ Preoperative and postoperative semen analysis parameters were separately averaged and used as the mean values for concentration, motility and morphology of all semen analyses (preoperatively and postoperatively) for each patient. Only semen analyses obtained 6 months or longer after varicocelectomy were considered evaluable.

Accepted for publication April 7, 1995.

Measurement of plasma hormone levels. Total circulating testosterone levels were measured using a commercial ^{125}I -iodine testosterone technique. Intra-assay and interassay coefficients of variation were 9.57% and 6.97%, respectively. Serum follicle-stimulating hormone and luteinizing hormone concentrations were determined using commercial radioimmunoassay kits. Preoperative and postoperative serum hormone levels were separately averaged and used as the mean values of testosterone, follicle-stimulating hormone and luteinizing hormone for each patient. Postoperative testosterone levels were measured at least 1 month after varicocelectomy. Preoperative and postoperative testosterone determinations were performed between 8 and 10 a.m. The normal range for each hormonal determination at our laboratory is 300 to 1,100 ng./dl. testosterone, 1.6 to 17.2 IU/l. follicle-stimulating hormone and 4.9 to 25.1 IU/l. luteinizing hormone.

Statistical analyses. Statistical analyses were performed using the 2-sample paired and unpaired t tests. Regression analyses were calculated using the method of least squares and analysis of variance. Statistics for 2-sample comparisons were reported as the mean plus or minus standard error of mean.

RESULTS

Change in serum testosterone. Serum testosterone levels in our study population ranged from 122 to 585 ng./dl. preoperatively and 111 to 1,020 ng./dl. postoperatively. Mean serum testosterone concentration for the study population increased from a preoperative level of 319 ± 12 to 409 ± 23 ng./dl. after varicocelectomy ($p < 0.0004$, fig. 1). Preoperative and postoperative mean testosterone concentrations were within the normal range (300 to 1,100 ng./dl.).

Size of varicocele and response to varicocelectomy. When stratifying the population according to size of varicocele, a trend was noted in that patients with grade I varicoceles achieved the greatest mean increase in serum testosterone and those with grade III varicoceles had the smallest increase after varicocelectomy (analysis of variance regression analysis, $r = -0.26$, $p = 0.06$, fig. 2). There was no significant difference between mean preoperative serum testosterone levels for different preoperative varicocele sizes (grade I— 311 ± 21 ng./dl., grade II— 324 ± 19 ng./dl. and grade III— 321 ± 26 ng./dl., analysis of variance regression analysis, $r = 0.047$, $p = 0.74$).

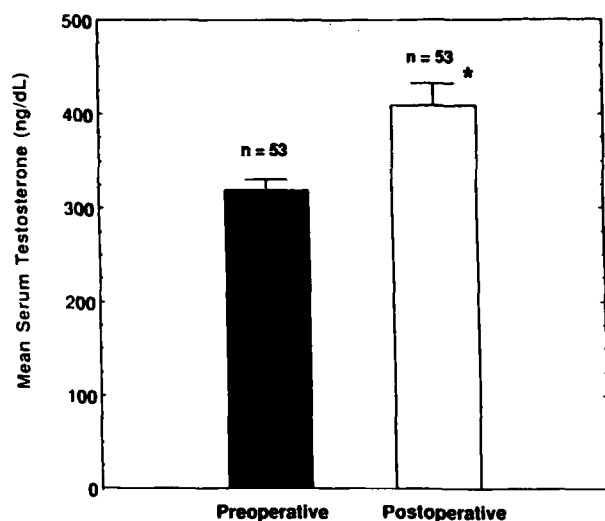


FIG. 1. Mean serum testosterone levels increased after varicocelectomy with $p < 0.0004$ (*).

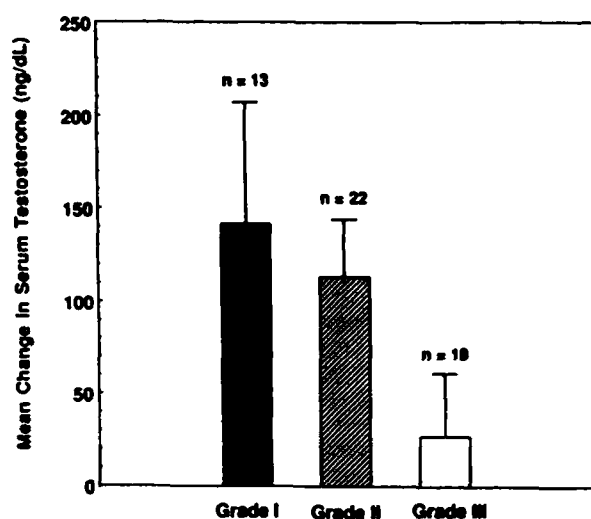


FIG. 2. Trend was noted between grade of varicocele and subsequent mean change in testosterone after varicocelectomy with $r = -0.26$ and $p = 0.06$ according to analysis of variance regression analysis.

Consistency of testis and response to varicocelectomy. The 32 patients with at least 1 firm testis preoperatively had a greater mean increase in serum testosterone postoperatively (144 ± 33 ng./dl.) than the 21 with bilaterally soft testes (10 ± 26 ng./dl.). This difference was highly significant ($p < 0.005$, fig. 3). There was no significant difference in mean preoperative testosterone levels for men with at least 1 firm testis (310 ± 16 ng./dl.) or bilaterally soft testes (332 ± 18 ng./dl., $p = 0.40$). Patients with firm testes also had significantly smaller varicoceles on average (grade 1.8 ± 0.13) than those with soft testes (grade 2.6 ± 0.11 , $p < 0.0001$).

Patient age and response to varicocelectomy. There was no correlation between patient age and preoperative testosterone ($r = -0.028$, $p = 0.84$), subsequent change in serum testosterone postoperatively ($r = -0.031$, $p = 0.83$) or grade of varicocele ($r = 0.042$, $p = 0.77$). Men with bilaterally soft testes were older on average (38 ± 2 years) than those with

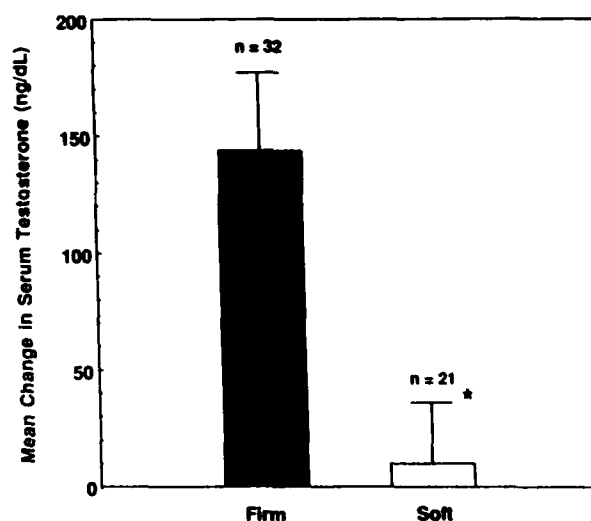


FIG. 3. Men with at least 1 firm testis had greater increase in serum testosterone after varicocelectomy compared to those with bilaterally soft testes with $p < 0.005$ (*).

at least 1 firm testis (35 ± 1 year) but the difference was not statistically significant ($p = 0.15$).

Preoperative testosterone and response to varicocelectomy. There was an inverse linear correlation between preoperative testosterone levels and subsequent change in testosterone after varicocelectomy ($r = -0.34$, $p < 0.013$, fig. 4). Of 35 patients (66%) with testosterone levels in the normal range preoperatively testosterone increased in 20 (57%), decreased but remained within the normal range in 10 (29%) and decreased below normal in 5 (14%). Of the remaining 18 patients (34%) with subnormal testosterone levels preoperatively (less than 300 ng/dl.) testosterone increased into the normal range in 10 (56%) after varicocele correction, increased but remained subnormal in 2 (11%) and decreased in 6 (33%) after varicocelectomy.

There was no consistent preoperative historical or physical finding that distinguished the men with decreased serum testosterone after varicocelectomy from others undergoing varicocelectomy. In addition, there was no significant difference in improvement in semen parameters compared to the entire study group. Those with decreased testosterone levels were slightly more likely to have large (grade III) varicoceles. Of the patients with decreased testosterone levels 53% had grade III varicoceles versus 26% with stable or increased serum testosterone levels but this finding did not achieve statistical significance ($p > 0.2$).

Changes in serum luteinizing hormone and follicle-stimulating hormone. No significant changes were noted in mean serum luteinizing hormone (10 ± 2 IU/l. preoperatively versus 9 ± 1 IU/l. postoperatively, $p = 0.76$) or follicle-stimulating hormone (20 ± 4 IU/l. preoperatively versus 19 ± 4 IU/l. postoperatively, $p = 0.90$) after varicocelectomy. Preoperative and postoperative mean luteinizing hormone concentrations were within the normal range, whereas mean follicle-stimulating hormone concentrations were slightly above normal before and after varicocelectomy.

Changes in semen analysis parameters. Sperm concentration and sperm motility increased postoperatively (fig. 5). Mean sperm concentration increased from 34 ± 6 to 45 ± 7 million per ml. postoperatively in 39 men ($p < 0.021$) and mean sperm motility increased from 34 ± 2 to $39 \pm 2\%$ following the operation in 38 ($p < 0.018$). No correlation was noted between change in testosterone and subsequent

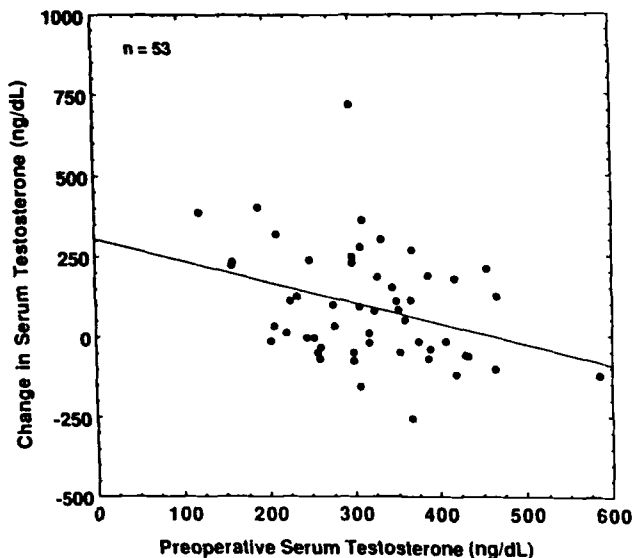


FIG. 4. Inverse correlation was noted between preoperative serum testosterone concentration and subsequent change in serum testosterone after varicocelectomy ($r = -0.34$, $p < 0.013$).

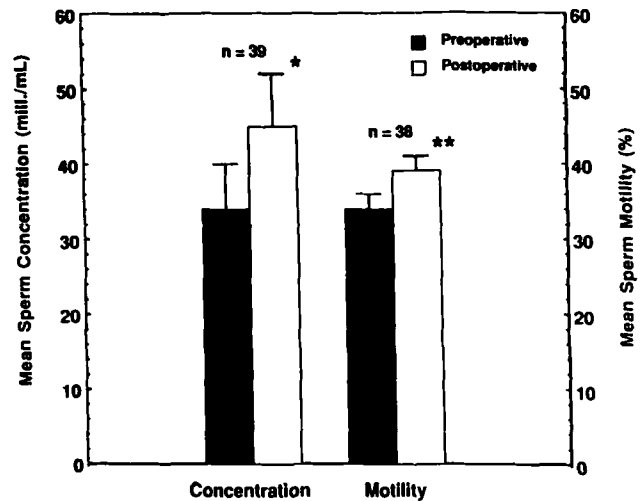


FIG. 5. Mean sperm concentration and motility increased after varicocelectomy with $p < 0.021$ (*) and $p < 0.018$ (**), respectively.

change in sperm concentration ($r = -0.22$, $p = 0.18$) or total motile sperm per ejaculate ($r = -0.10$, $p = 0.54$) although there was a negative correlation with subsequent change in sperm motility ($r = -0.34$, $p < 0.04$).

DISCUSSION

The exact mechanism by which a varicocele may affect hormonal function of the testis remains controversial. Studies demonstrating decreased testicular responsiveness to intramuscular injection of human chorionic gonadotropin suggest dysfunction at the Leydig cell level.^{2,12} Other studies of men with varicoceles show an exaggerated gonadotropin (luteinizing hormone and follicle-stimulating hormone) response to intravenous gonadotropin-releasing hormone.⁶ Blunted testosterone and exaggerated gonadotropin responses to human chorionic gonadotropin and gonadotropin-releasing hormone stimulation, respectively, that become normal after surgical correction of the varicocele support the hypothesis that the presence of a varicocele may induce testicular hormonal dysfunction that is reversed by varicocelectomy.

The effect of varicocelectomy on nonstimulated testosterone levels has not been extensively investigated. Hudson⁶ and Segenrich⁷ et al investigated only small populations (14 and 24 patients, respectively) with varicoceles and demonstrated no significant change in serum testosterone after varicocelectomy. Each group used a different surgical approach to varicocelectomy than in our study. Their techniques result in a higher percent of varicocele recurrence than the microsurgical approach that we use, which could contribute to the lack of significant change in serum testosterone in these 2 studies.¹⁰ However, it is more likely that the small patient populations in these studies did not provide the statistical power necessary to demonstrate a small increase in the naturally highly variable parameter of serum testosterone after varicocelectomy. In 1975 Comhaire and Vermeulen demonstrated an improvement of plasma testosterone in a small group of men who underwent surgical repair of varicoceles.⁸ However, this group was limited to 10 men of whom many had sexual inadequacy. The patients in this study were younger than 40 years with low preoperative plasma testosterone levels.

In our study of 53 patients (mean age 35 years) with preoperative testosterone levels ranging from 122 to 585 ng/dl. we demonstrated a statistically significant increase in mean serum testosterone following microsurgical inguinal varicocelectomy. This finding supports the concept that varicocelectomy can im-

prove Leydig cell function in men with varicoceles based on the measured increase in serum testosterone postoperatively. Others have shown that a varicocele is associated with impaired function of the terminal step of testosterone synthesis, that is conversion of 17-hydroxyprogesterone to testosterone by 17 α -hydroxyprogesterone aldolase.^{2, 13} The activity of this enzyme, like other enzymes, is temperature-dependent and may be adversely affected by the high intratesticular temperature in patients with varicoceles.¹⁴ It is possible that the physiological effect of varicocelectomy is to relieve the inhibition of the 17 α -hydroxyprogesterone aldolase enzyme.

Varicocelectomy does not appear to increase serum testosterone for all patients with varicoceles. The small negative correlation between preoperative testosterone and subsequent change in testosterone in our study population suggests that the primary effect of varicocelectomy is to normalize serum testosterone levels. Therefore, the procedure appears to benefit especially patients in whom varicoceles have a more detrimental effect on hormonal function of the testis, resulting in lower serum testosterone concentrations, while having a lesser effect (for example smaller absolute change in testosterone) in those who preoperatively had normal or low normal testosterone levels.

Our findings that men with at least 1 firm testis have a more favorable hormonal response to varicocelectomy than those with bilaterally soft testes is not surprising since firm testes represent the normal healthy state. The ability of firm testes to manufacture testosterone is likely to exceed that of bilaterally soft testes, which may have end stage dysfunction. The results of our study also demonstrate that men with smaller varicoceles tend to have greater increases in serum testosterone after varicocelectomy than those with larger varicoceles. This finding is in contrast to the study by Steckel et al, which demonstrated that greater improvements in sperm concentration, motility and fertility index (motile sperm concentration) occur after the repair of larger varicoceles.¹⁵ Furthermore, we noted no significant correlation between the magnitude of change in serum testosterone and improvements in sperm concentration or total motile sperm per ejaculate following varicocelectomy. Taken together these results suggest that, although improvements in Leydig cell function and spermatogenesis may occur simultaneously in patients postoperatively, the improvement in hormonal function may be independent of improvements in spermatogenesis. The effect of varicocelectomy on spermatogenesis may be related to changes in venous pressure, temperature or intratesticular interstitial fluid volume, not hormonal changes alone. In addition, germ cells are known to be more sensitive than Leydig cells to noxious stimuli. Therefore, it is expected that hormonal responses and changes in spermatogenesis after varicocelectomy may not occur simultaneously in all patients.

CONCLUSIONS

Our study demonstrates that varicocelectomy can increase serum testosterone, especially in patients with abnormally

low serum testosterone levels. Although improvement in serum testosterone does not necessarily cause a direct improvement in semen quality, varicocelectomy may improve hormonal and spermatogenic function.

REFERENCES

1. Weiss, D. B., Rodriguez-Rigau, L. J., Smith, K. D. and Steinberger, E.: Leydig cell function in oligospermic men with varicocele. *J. Urol.*, **120**: 427, 1978.
2. Ando, S., Giacchetto, C., Colpi, G., Panno, M. L., Beraldi, E., Lombardi, A. and Sposato, G.: Plasma levels of 17-OH-progesterone and testosterone in patients with varicoceles. *Acta Endocrinol.*, **102**: 463, 1983.
3. Sirvent, J. J., Bernat, R., Navarro, M. A., Rodriguez Tolra, J., Guspi, R. and Bosch, R.: Leydig cell in idiopathic varicocele. *Eur. Urol.*, **17**: 257, 1990.
4. Swerdloff, R. S. and Walsh, P. C.: Pituitary and gonadal hormones in patients with varicocele. *Fertil. Steril.*, **26**: 1006, 1975.
5. Adamopoulos, D., Lawrence, D. M., Vassilopoulos, P., Kapolla, N., Kontogeorgos, L. and McGarrigle, H. H.: Hormone levels in the reproductive system of normospermic men and patients with oligospermia and varicocele. *J. Clin. Endocrinol. Metab.*, **59**: 447, 1984.
6. Hudson, R. W., Perez-Marrero, R. A., Crawford, V. A. and McKay, D. E.: Hormonal parameters of men with varicoceles before and after varicocelectomy. *Fertil. Steril.*, **43**: 905, 1985.
7. Segenreich, E., Shmueli, H., Singer, R. and Servadio, C.: Andrological parameters in patients with varicocele and fertility disorders treated by high ligation of the left spermatic vein. *Int. J. Fertil.*, **31**: 200, 1986.
8. Comhaire, F. and Vermeulen, A.: Plasma testosterone in patients with varicocele and sexual inadequacy. *J. Clin. Endocrinol. Metab.*, **40**: 824, 1975.
9. Dubin, L. and Amelar, R. D.: Varicocele size and results of varicocelectomy in selected subfertile men with varicocele. *Fertil. Steril.*, **21**: 606, 1970.
10. Goldstein, M.: Surgery of male infertility and other scrotal disorders. In: *Campbell's Urology*, 6th ed. Edited by P. C. Walsh, A. B. Retik, T. A. Stamey and E. D. Vaughan, Jr. Philadelphia: W. B. Saunders Co., vol. 3, chapt. 87, pp. 3114-3147, 1992.
11. WHO Laboratory Manual for the Examination of Human Semen and Sperm-Cervical Mucus Interaction, 3rd ed. Cambridge: Cambridge University Press, 1992.
12. Castro-Magana, M., Angulo, M., Canas, A. and Uy, J.: Leydig cell function in adolescent boys with varicoceles. *Arch. Androl.*, **24**: 73, 1990.
13. Takeyama, M., Honjoh, M., Kodama, M., Sakaguchi, H., Koh, E., Kondoh, N., Fujioka, H., Nakamura, M., Namiki, M., Okuyama, A., Matsumoto, K. and Sonoda, T.: Testicular steroids in spermatic and peripheral veins after single injection of hCG in patients with varicocele. *Arch. Androl.*, **24**: 207, 1990.
14. Goldstein, M. and Eid, J-F.: Elevation of intratesticular and scrotal skin surface temperature in men with varicocele. *J. Urol.*, **142**: 743, 1989.
15. Steckel, J., Dicker, A. P. and Goldstein, M.: Relationship between varicocele size and response to varicocelectomy. *J. Urol.*, **149**: 769, 1993.

RELATIONSHIP BETWEEN VARICOCELE SIZE AND RESPONSE TO VARICOCELECTOMY

JOPH STECKEL, ADAM P. DICKER AND MARC GOLDSTEIN*

From the Division of Urology, James Buchanan Brady Foundation, The New York Hospital-Cornell Medical Center and The Population Council, Center for Biomedical Research, New York, New York

ABSTRACT

We studied the relationship between varicocele size and response to surgery in 86 men with a unilateral left varicocele who reported either infertility (83), pain (1) or pain and testicular atrophy (2). Varicoceles were graded according to size: grade 1—small (22 patients), grade 2—medium (44) and grade 3—large (20). Sperm count, per cent motility, per cent tapered forms and fertility index (sperm count times per cent motility) were measured preoperatively and postoperatively.

Preoperatively, men with grade 3 varicocele had lower sperm counts and poorer fertility indexes compared to men with grades 1 and 2 varicocele. Sperm concentration improved significantly in men with grade 2 (33 ± 5 million per cc preoperatively to 41 ± 6 million postoperatively, $p < 0.04$) and grade 3 (18 ± 5 million preoperatively to 32 ± 7 million postoperatively) varicocele after microsurgical ligation of the varicocele. Motility improved significantly in men with grade 3 varicocele. Decrease in per cent tapered forms was significant in all groups. A comparison of per cent change in fertility index among the groups revealed that men with grade 3 varicocele improved to a greater degree (128%) than men with grade 1 (27%) or grade 2 (21%) varicocele. Pregnancy rates 2 years postoperatively were 40% for grade 1, 46% for grade 2 and 37% for grade 3 varicocele patients. The difference in pregnancy rates among the groups was not statistically significant.

In conclusion, infertile men with a large varicocele have poorer preoperative semen quality but repair of the large varicocele in those men results in greater improvement than repair of a small or medium sized varicocele.

KEY WORDS: varicocele, infertility, semen

Varicoceles were recognized in the first century when the Greeks accurately observed that "the veins are swollen and twisted over the testicle, which becomes smaller than its fellow."¹ Varicoceles are the most frequently encountered, surgically correctable cause of male infertility.² The incidence in the unscreened, healthy male population is 15%. However, approximately 35% of all men evaluated for infertility have a varicocele.³ The exact pathophysiology of varicocele is incompletely understood. Most recent studies on the mechanism of varicocele-induced infertility note an increase in testicular temperature due to impairment of the countercurrent heat exchange mechanism.⁴⁻⁶

MacLeod first described the triad of oligospermia, decreased motility, and increased percentage of immature and tapered forms characteristic of infertile men with varicocele.⁷ Following varicocele ligation many investigators report an improvement in semen quality in 60 to 70% of the patients and pregnancy rates of 20 to 40%.³ Although several studies indicate that larger varicoceles are associated with greater impairment of spermatogenesis,⁸⁻¹¹ others suggest that response to surgery is independent of varicocele size.^{3,5,10,12} We correlated semen analyses before and after microsurgical varicocelectomy with varicocele size in an attempt to determine how varicocele size influences response to an operation.

METHODS

Patients. A total of 86 men with a unilateral left varicocele presented for surgery because of either infertility at least 1 year in duration (83), pain (1) or testicular atrophy and pain (2). Men with bilateral varicocele were excluded. Patient age ranged

from 16 to 57 years (mean 34). The patients were examined while standing in a warm room. Varicocele size was classified as grade 1 (small)—distinct impulse palpated with Valsalva's maneuver, no tortuosity and less than 1 cm. in diameter; grade 2 (medium)—palpable dilation greater than 1 cm. and with tortuosity detected with Valsalva's maneuver, and grade 3 (large)—easily visualized through the scrotal skin and palpable without Valsalva's maneuver. All gradings were performed by the same examiner.

Semen analysis. Semen was obtained by masturbation after a minimum of 3 days of abstinence. An average of 2.97 semen analyses were done preoperatively. In 2 patients less than 20 years old undergoing surgery for pain and atrophy only 1 semen analysis was done preoperatively and postoperatively. In infertile men semen analyses were obtained at 3 and 6 months postoperatively, and every 6 months thereafter or until pregnancy occurred. The mean number of postoperative analyses was 2.72. Specimens were examined within 1 hour of collection and assessed for sperm concentration, per cent motility and morphology. Sperm counts were performed with a Makler chamber.[†] Motility was evaluated by video micrography. Morphology was assessed after preparation with the Papanicolaou stain. Mean values of all preoperative and postoperative specimens were used as the preoperative and postoperative values for each patient. Normal values for our semen laboratory are sperm concentration 25 to 200 $\times 10^6$ /ml., sperm motility more than 40% and tapered forms less than 4%.

Surgical technique. All men underwent ambulatory unilateral varicocelectomy with a microsurgical inguinal technique with delivery of the testes.¹³ Briefly, the testis is delivered through a 2 to 3 cm. inguinal incision, and all external spermatic and gubernacular veins are ligated. The testis is returned to the scrotum and the spermatic cord is dissected under the operating

† Selfi-Medical Instruments, Haifa, Israel.

Accepted for publication October 2, 1992.

Read at annual meeting of American Urological Association New Orleans, Louisiana, May 13-17, 1990.

* Requests for reprints: Division of Urology, F900, The New York Hospital-Cornell Medical Center, 525 East 68th St., New York, New York 10021.

microscope. The testicular artery and lymphatics are identified and preserved. All internal spermatic veins are doubly ligated with metal clips or 4-zero silk sutures and divided. The vas deferens and its vessels are preserved.

Statistical analyses. Statistical analyses were performed with the paired t test (Wilcoxon signed rank test) or the 2-sample t test (Mann-Whitney test).

RESULTS

Of 86 patients studied 22 had grade 1, 44 grade 2 and 20 grade 3 varicoceles (table 1). Therefore, in this population of predominantly infertile men grade 2 varicoceles were twice as common as grade 1 or 3. Mean sperm concentrations increased significantly after repair of grades 2 and 3 varicoceles. Sperm counts increased from 33 ± 5 million per cc preoperatively to 41 ± 6 million per cc postoperatively in the grade 2 group ($p < 0.04$) and from 18 ± 5 million per cc preoperatively to 32 ± 7 million per cc postoperatively in the grade 3 group ($p < 0.02$, fig. 1). Sperm counts after repair of grade 1 varicoceles increased from 38 ± 7 to 46 ± 9 million per cc but this difference was not statistically significant. Improvements in per cent motility were significant in grade 3 varicocele patients, in whom varicocele ligation increased motility from 30 ± 4 to $41 \pm 4\%$ ($p < 0.01$, fig. 2). All groups showed a significant decrease in per cent tapered forms (fig. 3).

A fertility index (motile sperm concentration) was calculated by multiplying sperm concentration by per cent motility.⁹ Fer-

TABLE 1. Results after surgical ligation of left varicoceles

Grade	No. Pts.	Sperm concentration (million/cc)*		% Motility*	
		Preop.	Postop.	Preop.	Postop.
1	22	38 ± 7	46 ± 9	39 ± 2	45 ± 3
2	44	33 ± 5	41 ± 6	39 ± 3	40 ± 3
3	20	18 ± 5	32 ± 7	30 ± 4	41 ± 4

* Values are given as mean plus or minus standard error.

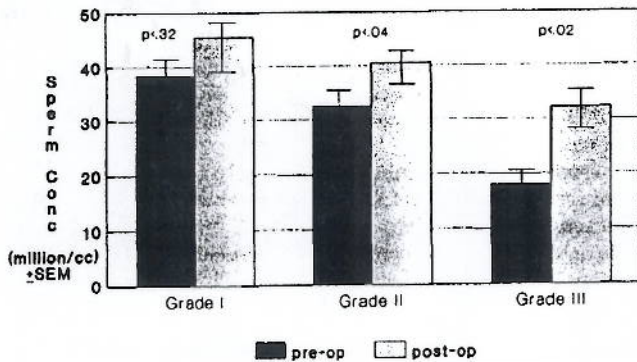


FIG. 1. Left varicocele: sperm concentration

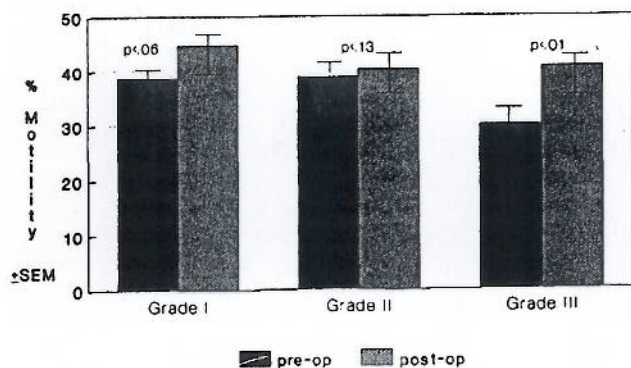


FIG. 2. Left varicocele: % motility

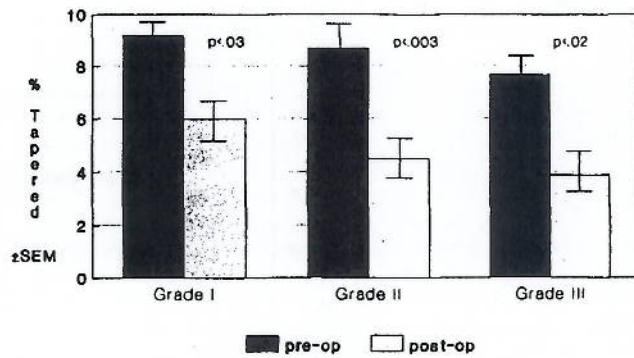
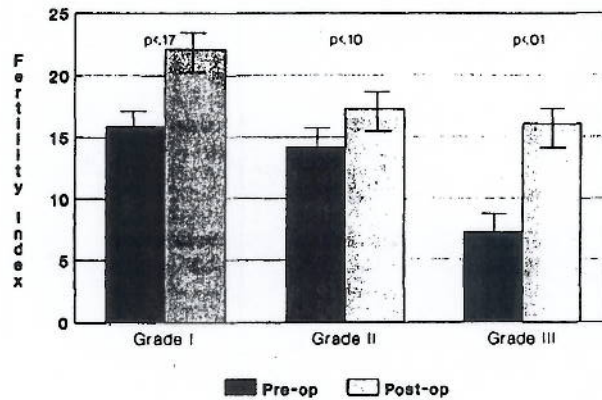


FIG. 3. Left varicocele: % tapered forms



Fertility index = (sperm conc) x (% motility)/100 ± SEM

FIG. 4. Left varicocele: fertility index

TABLE 2. Postoperative changes

Grade	Fertility Index (%)	Sperm Concentration (%)	Motility (%)
1	27	21	15
2	21	24	3
3	128	94	37

tility index increased marginally in men with grade 2 varicocele ($p < 0.10$) and significantly in men with grade 3 varicocele ($p < 0.01$, fig. 4). Preoperatively, men with a large varicocele had lower sperm concentrations compared to those with a medium sized ($p < 0.05$) and small ($p < 0.01$) varicocele. Similarly, men with a large varicocele had poorer fertility indexes compared to those with a medium sized ($p < 0.05$) and small ($p < 0.01$) varicocele.

The per cent change in fertility index, sperm concentration and per cent motility among groups of patients was compared (table 2). In men with a grade 3 varicocele the fertility index improved to a greater degree compared to those with a grade 1 ($p < 0.03$) or grade 2 ($p < 0.03$) varicocele. A 27% improvement was noted in the grade 1 group, 21% for grade 2 and 128% for grade 3 ($p < 0.03$). There was no significant per cent change in fertility index when comparing grades 1 and 2 ($p < 0.10$). Similarly, a marginally significant difference in per cent improvement in sperm concentration was detected between grades 1 (21%) and 3 (94%, $p < 0.06$). Differences in improvements in per cent motility were significant between grades 2 and 3 groups ($p < 0.03$). There was no significant difference when comparing grades 1 and 2 ($p < 0.63$). The pregnancy rates 2 years after surgery for male factor infertility in men available for followup were 40% (8 of 20) for grade 1, 46% (19 of 41) for grade 2 and 37% (7 of 19) for grade 3. The differences in pregnancy rates

among the groups were not statistically significant. The overall pregnancy rate was 42.5% (34 of 80 patients).

DISCUSSION

It has been shown previously that spermatogenesis and fertility in infertile men with a varicocele improve after varicocele ligation.^{8,13-16} In our study varicoceles were graded by size and response to surgery was compared. Postoperative sperm concentration, per cent motility, per cent of tapered forms, and fertility index all improved more significantly in the group with large versus small varicoceles. Our results confirm the findings of Tinga et al,¹¹ and Scott and Young,¹⁴ who also demonstrated greater improvement after repair of a large varicocele.

Our data clearly show that semen parameters are poorer preoperatively in men with a large varicocele and their response to an operation is more dramatic. Our results also confirm those of Dubin and Amelar showing no difference in pregnancy rates after repair of small versus large varicoceles.¹⁰ A possible explanation is our finding that although men with a large varicocele begin with significantly poorer semen quality than men with a small varicocele, surgery results in a more dramatic improvement in those with a large varicocele so that postoperatively there is no significant difference in either semen parameters or pregnancy rates.

These findings clearly indicate that repair of a large varicocele results in a greater improvement in semen quality than repair of a small varicocele. This information is of value when counseling infertile couples regarding the expected outcome of varicocele surgery.

REFERENCES

1. Howards, S. S.: Varicocele. *Fertil. Steril.*, 41: 356, 1984.
2. Cockett, A. T. K., Takihara, M. and Cosentino, M. J.: The varicocele. *Fertil. Steril.*, 41: 5, 1984.
3. Marks, J. L., McMahon, R. and Lipshultz, L. I.: Predictive parameters of successful varicocele repair. *J. Urol.*, 136: 609, 1986.
4. Zorngiotti, A. W. and MacLeod, J.: Studies in temperature, human semen quality, and varicocele. *Fertil. Steril.*, 24: 854, 1973.
5. Glezerman, M., Rakowszczyk, M., Lunenfeld, B., Beer, R. and Goldman, B.: Varicocele in oligospermic patients: pathophysiology and results after ligation and division of the internal spermatic vein. *J. Urol.*, 115: 562, 1976.
6. Goldstein, M. and Eid, J.-F.: Elevation of intratesticular and scrotal skin surface temperature in men with varicocele. *J. Urol.*, 142: 743, 1989.
7. MacLeod, J.: Seminal cytology in the presence of varicocele. *Fertil. Steril.*, 16: 735, 1965.
8. Scott, L. S.: Varicocele ligation with improved fertility. *J. Reprod. Fertil.*, 1: 45, 1960.
9. Scott, L. S.: Varicocele: a treatable cause of subfertility. *Brit. Med. J.*, 1: 788, 1961.
10. Dubin, L. and Amelar, R. D.: Varicocele size and results of varicocelectomy in selected subfertile men with varicocele. *Fertil. Steril.*, 21: 606, 1970.
11. Tinga, D. J., Jager, S., Bruijnen, C. L., Kremer, J. and Mensink, H. J.: Factors related to semen improvement and fertility after varicocele operation. *Fertil. Steril.*, 41: 404, 1984.
12. Greenberg, S. H., Lipshultz, L. I. and Wein, A. J.: Experience with 425 subfertile male patients. *J. Urol.*, 119: 507, 1970.
13. Goldstein, M., Gilbert, B. R., Dicker, A. P., Dwosh, J. and Gnecco, C.: Microsurgical inguinal varicocelectomy with delivery of the testis: an artery and lymphatic sparing technique. *J. Urol.*, 148: 1808, 1992.
14. Scott, L. S. and Young, D.: Varicocele: a study of its effects on human spermatogenesis, and of the results produced by spermatic vein ligation. *Fertil. Steril.*, 13: 325, 1962.
15. Charney, C. W.: Effect of varicocele on fertility. Results of varicocelectomy. *Fertil. Steril.*, 13: 47, 1962.
16. Dubin, L. and Amelar, R. D.: Varicocelectomy: 986 cases in a twelve-year study. *Urology*, 10: 446, 1977.

[Click here to print](#)


MailOnline

How a form of varicose veins can make men depressed and infertile

By [John Naish](#)

Last updated at 6:56 PM on 15th July 2011

Like 21



Baby joy: Treatment of varicoceles could help more men become fathers

More men than ever suffer from depression and male infertility rates are also on the rise.

Now an eminent surgeon believes he's identified a significant cause of both — varicose veins in the testes, or varicoceles, a condition affecting up to 15 per cent of men.

The suggestion is that thousands of men could avoid these problems with low-risk preventive surgery.

Just like normal varicose veins in the legs, varicoceles are caused by the failure of the valves inside the vein — these valves help keep the blood flowing back to the heart.

If they fail, the blood pools in the vein, stretching the walls and enlarging the vein.

It's not clear why this happens in men, but it is known that the resultant vein-stretching can steadily worsen with age.

Professor Marc Goldstein, of Cornell University in the U.S., says that when varicoceles fill with excessive amounts of warm blood, the testes heat up.

As a result, they no longer function properly. This prevents them from producing two crucial substances: sperm and the male hormone testosterone. Falling sperm counts are a key cause of growing male infertility.

Low testosterone in men only adds to the problem, as it can cause falling sex drive and erectile difficulties.

On top of this, shortage of the male hormone is also linked to serious clinical depression. It can also cause bone-thinning osteoporosis in later life.

While thousands of British men have varicoceles, studies show that they also occur in 6 per cent of children at age ten, and in 13 per cent of adolescents.

In a controversial paper in the respected British Journal of Urology International, Professor Goldstein — a fertility surgeon who has also practised in Britain — suggests that men with visible evidence of varicoceles should have early surgery to prevent them from suffering falling levels of sperm and testosterone.


(The other, less serious, form of varicoceles are not visible, but can be detected by feeling the testes — they are found in 12 per cent of the male adult population.)

'Varicoceles are a much more serious problem than previously thought,' explains Professor Goldstein. 'Because blood pools inside these veins, it raises the temperature of anything around them.'

'This is a problem, because testicles need to be between two and four degrees centigrade below body temperature in order to function.'

'That is why they hang outside the body. When they are filled with warm blood, it takes them up to body temperature, so they fail to produce sperm and testosterone properly. Fertility levels plummet.'

In a study involving 800 men, Professor Goldstein set out to discover whether men's hormone levels would improve after microsurgery to repair the veins.



Not so super: Tight-fitting pants can reduce sperm count

The study found that 3 per cent had visible varicoceles and falling testosterone levels — when they were given the surgery, 70 per cent of these patients saw significant rises in their testosterone levels.

On average, these rose from an average 416 nanograms per decilitre (ng/dL) to around 600 — the average for a normal 45-year-old man.

Dr Ian Banks, the president of the Men's Health Forum, says more research needs to be done before men go rushing for varicocele surgery.

However he adds: 'Anything that threatens to cause a reduction in testosterone levels has to be taken seriously.'

'Low testosterone causes other serious problems such as low sperm count, osteoporosis and diminished libido and mood. These problems tend to get worse later in life.'

Current medical wisdom is to leave varicoceles alone unless they're thought to be directly lowering sperm count by blocking tubes leading from the testes or causing physical discomfort.

But Professor Goldstein believes this policy should change.

He says: 'It is far easier to prevent future infertility and low testosterone than it is to cure them once the damage has been fully done.' The men most at risk, he says, are those with 'grade-three' varicoceles.

'These are the biggest ones — veins that you can see through the skin. They look like a bag of worms,' says Professor Goldstein. Grade two is when you can feel them; in grade one they can be detected when you cough or strain.

THE OTHER WAYS A MAN CAN LOSE HIS FERTILITY

- **Low IQ:** Men who scored badly in intelligence tests have lower sperm counts than those at the top of

the class, according to research by King's College, London. This may be because smarter men do more to protect their overall health.

- **Cycling:** Studies have shown male cyclists can suffer fertility problems that increase with the number of miles they ride each week. Researchers have blamed narrow seats and tight cycling shorts.
- **Antidepressants:** Certain antidepressant drugs, called selective serotonin reuptake inhibitors, may cause changes in the sperm DNA of half of the men taking them, suggests American research.
- **Obesity:** Fat tissue produces the female hormone oestrogen, which interferes with the action of testosterone and may lead to mis-shaped sperm.
- **Mobile phones:** A Canadian study suggests radiation from mobiles may interfere with hormones that are crucial for sperm production. Further studies are needed, but some experts suggest that men keep mobiles out of their pockets and off their belts.

Among infertile men, nearly half have varicoceles, according to research in the journal *Fertility and Sterility*.

Professor Goldstein believes the operation might help improve sperm counts in thousands of couples who are undergoing expensive assisted-reproduction techniques.

Meanwhile, he is urging men to start examining themselves for the problem. 'Stand up after a warm shower or bath and look at yourself in the mirror.

'If it looks like you have a bag of worms under the skin next to or above one or both testicles, then see a doctor,' he says, adding: 'Modern surgical techniques have very low rates of failure and complications.

'It is such a safe operation that it is definitely worth doing to prevent future problems with infertility and testosterone levels.'

Andrew Pinnington, 32, a sales representative from Lichfield, Staffs, knows first-hand how such operations can be easy and straightforward.

He sought help because he was suffering from a dull ache in his groin.

His GP diagnosed a varicocele and referred him to a specialist, Dr Paul Crowe, a radiologist at the Priory Hospital in Birmingham.

Dr Crowe uses a relatively new procedure where, under X-ray guidance, a very fine tube is fed into the vein, stopping just short of the testicles.

Tiny coils are then injected into the vein to block the blood flow.

Another nearby vein naturally takes over the blood supply.

All that Andrew had to undergo was a small injection of local anaesthetic. 'It took about half an hour and I didn't even need a plaster on the little nick they made on my groin,' he says.

'After a couple of hours they sent me home. I had no pain and was back at work the next day.' Andrew had the operation two years ago.

'Since then, we've had a baby boy, Henry. So I can safely say there are no problems with fertility.'

However, the use of surgery on varicoceles to tackle infertility is controversial. A review in 2009 of previous studies by the highly respected Cochrane Database concluded that, in general, varicocele operations do not help sub-fertile men boost their sperm counts.

But a study in *Fertility and Sterility* last March found that 'varicocele repair has been shown to reverse a spectrum of effects contributing to men with impaired fertility'.

Professor Goldstein's recommendations differ here in a crucial respect; he wants to use surgery to prevent falling sperm counts and testosterone levels before any damage happens.

There is another reason for medical resistance to the idea: varicocele operations in the UK can still involve outdated methods such as high ligation — physically tying up the vein in the scrotum — which carry a much

higher risk of complications.

Dr Crowe says that older-style, invasive methods can be necessary for some patients' cases, but for the majority, microsurgery should be the option because it has a 'significantly lower' rate of complications.

He adds: 'Professor Goldstein's research is an interesting avenue that is worth pursuing. But we still need more good-quality studies here.'

FOCUS ON **Your Health**

THE PULSE

Progress comes in small packages. The percentage of adults engaging in leisure-time physical activity rose from 29.8% in 1998 to 30.2% in 1999 and 31.9% in 2000.

SOURCE: NATIONAL CENTER FOR HEALTH STATISTICS



Infertility: A Guy Thing

Sparse or sluggish sperm can make parenthood inconceivable. But there's help.


BY TEMMA EHRENFELD

PATRICK JERMYN WILL NEVER forget his first experience with a urologist. He and his wife, Jennifer, had been trying unsuccessfully for a year and a half to get pregnant. He was a 34-year-old lawyer, she a 30-year-old schoolteacher, and they were both in fine health. But after looking at two semen samples and conducting a routine exam, the urologist offered a harsh verdict. Patrick's sperm quality was so poor that he might never father a child naturally.

Women have been blamed for barren marriages from the Bible on. In truth, a fifth of all infertility stems exclusively from male factors, and an additional third involves both partners. Gynecological problems account for only 40 percent of infertility, yet doctors still tend to view it as a female condition. The good news, as Patrick Jermyn discovered, is that the most common male problems can be fixed.

The top enemies can be described in two words: heat and blockage. In order to produce healthy sperm, the testicles need to be four degrees cooler than the rest of the body. That's why they're mounted outside the torso. Sperm cells spend three months growing within the testicles, then travel through an ultrathin coiled tube (the epididymis), where they learn how to swim. Finally they move into the vas deferens—two tubes, one from each testicle—which contract to make ejaculation possible.

The most common cause of male infertility is a varicocele, a cluster of enlarged veins in the scrotum. These varicose veins may cause no symptoms (some men experience a slight ache when lifting heavy objects), but the heat they generate may wreak havoc on sperm production. Men with varicoceles can be fertile, but the condition is associated with low sperm counts, sperm that swim poorly and sperm so misshapen they can't enter an egg. Jermyn's local urologist checked him for varicoceles but didn't see any—probably because the



DELIGHT: Surgery for a varicose vein helped make Jermyn a dad

patient was sitting on a cold examining table and experiencing the "Seinfeld" shrinkage effect. Later, at Jennifer's insistence, Patrick visited New York's Weill Cornell Medical Center. This time he got to sit on a heating pad during the exam—and the urologist, Dr. Marc Goldstein, noticed the telltale tiny, thick spot on his scrotum.

Goldstein was able to repair it with a minimally invasive surgical procedure. The operation improves sperm counts, and studies suggest that it more than doubles a couple's odds of achieving pregnancy within a year—from 17 percent to 43 percent. Three months after the procedure, Patrick's sperm looked normal.

FOCUS ON YOUR HEALTH

Besides checking for varicoceles, a good urologist also looks for swelling in the epididymis and vas deferens. Common venereal infections, such as chlamydia and gonorrhea, can leave behind scar tissue that blocks the epididymis. And urologists often discover that a man's vas deferens has been injured in a past hernia operation—with the same results as an intentional vasectomy. Roughly a fifth of all male infertility involves these mechanical blockages. Fortunately, most of them can be corrected with microsurgery, restoring typical sperm counts in men who would otherwise produce none.

For a normal, healthy male, staying fertile doesn't require surgery, but it does take some care. Any form of substance abuse, from smoking cigarettes to snorting cocaine, can hamper sperm production. If you're concerned about fertility, stick to two drinks twice a week. Even a single drinking binge can temporarily disrupt the process, resulting in sperm with deformed heads and curled tails. You should also ask your doctors if any of your prescriptions can hamper fertility. The danger zone surprisingly includes popular items like the ulcer drug Tagamet (cimetidine), the heart drug Crys-todigin (digitalis), the alpha blockers and calcium blockers used to treat high blood pressure and standard antibiotics. Sperm quality usually rebounds once the drug is discontinued.

If you're getting clean, lose the Mick Jagger underwear, too. Anything that heats the testicles—steam rooms, a fever, long drives—can reduce your odds of fatherhood. (Three thousand years ago, Japanese men took daily hot baths as a form of contraception.) Finally, look into occupational hazards. "I've seen truckdrivers impregnate their wives after they switched to dispatching," says Goldstein. "And I had a pizza-parlor owner whose wife got pregnant when he stayed away from the oven."

Finally, couples who discover that the man has a fertility problem shouldn't assume they will never be parents. A year to the day after Patrick Jermyn left the hospital without his varicocele, Jennifer left another hospital with their son, Ryan Patrick. Last month Ryan had his first birthday. ■

Marc Goldstein, M.D., F.A.C.S.



Weill Cornell Medical College
Cornell Institute for Reproductive Medicine

Center for Male Reproductive Medicine and Microsurgery

Marc Goldstein, MD, DSc (hon), FACS is the Matthew P. Hardy Distinguished Professor of Reproductive Medicine, and Urology at Weill Cornell Medical College of Cornell University; Surgeon-in-Chief, Male Reproductive Medicine and Surgery; and Director of the Center for Male Reproductive Medicine and Microsurgery at the New York Presbyterian Hospital Weill Cornell Medical Center. He is Senior Scientist with the Population Council's Center for Biomedical Research, located on the campus of Rockefeller University.

Dr. Goldstein is the only male infertility specialist cited in the American Health Magazine special issue on *The Best Doctors in America*. He is listed in New York Magazine's *Best Doctors in New York* (2011). He is listed in the books *Best Doctors in America* (2011), The Castle Connolly Guide *America's Top Doctors* (2011) and *How to Find the Best Doctors*, New York Metro Area (2011), as well as *Who's Who in America* (2011). He is a board certified urologic surgeon and member of a dozen national and international medical societies dealing with male infertility and reproduction. He is Past-President of the Society for Male Reproduction and Urology of the American Society for Reproductive Medicine, and recipient of the 1997 *Master Teacher in Urology Award* and the 2002 *Distinguished Alumni Achievement Award* from his alma mater. He has been honored by RESOLVE and the American Infertility Association for his "*Outstanding Dedication and Commitment to Family Building*". He received the 2002 *John Kingsley Lattimer Award in Urology* from the Kidney and Urology Foundation of America and is the recipient of the 2007 *Lifetime Achievement Award* of The American Fertility Association. He received an *honorary Doctor of Science* in 2008 from the State University of New York, Downstate Medical Center. In 2009, he received the *John Coleman, M.D. Teaching Award* from the Department of Urology at Weill Cornell Medical College.

Dr. Goldstein is internationally renowned for his pioneering work in vasectomy reversals and microsurgical repair of varicoceles and blockages. He has performed over 1,000 microsurgical vaso-vasostomies and vaso-epididymostomies. His technique of microsurgical vasectomy reversal, as published in a peer-reviewed journal, yields the highest reported sperm return and pregnancy rates. He developed a microsurgical technique of varicocelectomy in 1984 and has performed over 3000 cases with the lowest reported failure and complication rates. He was the first American surgeon to be trained in, and perform, the Chinese method of No-Scalpel Vasectomy.

Dr. Goldstein has authored or co-authored over 250 journal articles and book chapters. He is the author of *Surgery of Male Infertility*, the first textbook on the subject. He is co-author of *The Couple's Guide to Fertility* (Broadway/Rand House 2001, 3rd edition), *The Vasectomy Book* (Houghton Mifflin), *Reproductive Medicine Secrets* (Hanley & Belfus, 2004), *A Baby at Last* (Simon & Schuster 2010), and the upcoming *Male Infertility* (Cambridge University Press). He is on the editorial board of the medical journals *Microsurgery* and *Fertility and Sterility*. He has also been featured in interviews on numerous major media outlets including NBC's *The Today Show*, ABC's *Good Morning America*, ABC's *Eyewitness News*, *Newsweek*, *The Wall Street Journal* and *The New York Times*.

A *summa cum laude* graduate of the College of Medicine, State University of New York – Downstate Medical Center in Brooklyn, New York, Dr. Goldstein worked as a resident in general surgery at Columbia Presbyterian Hospital in New York. After three years overseas in the U.S. Air Force, attaining the rank of Major and flying in F4 Phantom aircraft as a Flight Surgeon, Dr. Goldstein was trained in urology at Downstate Medical Center. He continued his post-graduate training in reproductive physiology at the Population Council, Center for Biomedical Research, located on the campus of Rockefeller University, and at the Rockefeller University Hospital.

Dr. Goldstein is a long distance runner and triathlete who races regularly and has completed 20 New York City Marathons.

Dr. Goldstein's office address is: Institute for Reproductive Medicine, Weill-Cornell Medical College, Box 580, 525 E 68th Street, New York, NY 10065. The telephone number to make an appointment is (212) 746-5470. The fax number is (212)746-0977. For further information about his male infertility practice, please visit his website at www.maleinfertility.org.

"State-of-the-Art Compassionate Care for the Infertile Couple"